

## Anatomy Lecture Notes Section 5: The Respiratory System

Arguably, the chief function of the respiratory system is to supply the lungs with oxygen (O<sub>2</sub>) and to eliminate carbon dioxide (CO<sub>2</sub>) from the body that is constantly being generated by the tissues. Our approach to this system is to recognize that this main function can be divided into more discrete functions, as seen below.

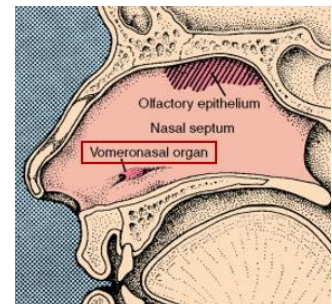
### General Functions of the Respiratory System

1. **Ventilation** of air to and from the external environment and the body, involving:
  - a. Inspiration – bringing air into the lungs.
  - b. Expiration – expelling air from the lungs.
2. Creating a large **Surface Area for Gas Exchange** – An alveolus is the site of gas exchange within the lungs and the pulmonary capillaries of the cardiovascular system. There are approximately **300 million alveoli** contained in the 2 lungs (right and left). The surface area provided for gas exchange in the body is estimated to be approximately the size of a tennis court. This is an enormous surface area effectively contained within the thoracic cavity.
3. **Regulation of the pH** of body fluids – CO<sub>2</sub> content in the blood effects the body pH by way of the bicarbonate buffer system. Here is the equation:  $\text{CO}_2 + \text{H}_2\text{O} \rightleftharpoons \text{H}_2\text{CO}_3 \rightleftharpoons \text{H}^+ + \text{HCO}_3^-$ . Therefore, the respiratory rate influences the elimination and/or accumulation of CO<sub>2</sub> in the body and this will impact the pH of body fluids.
4. **Sound Production** – the passage of air through the vocal folds of the larynx (voice box) can generate different sounds with variations in pitch (frequency) and amplitude (volume) of the sound depending on the air flow through the glottis of the vocal folds, which is also influenced by the movement of these vocal folds as air passes through them.
5. **Olfaction** - Sense of Smell. Branches of cranial nerve I (Olfactory N.I) travel through the olfactory foramina of the cribriform plate of the ethmoid bone down into the nasal cavity, where the chemical receptors (chemoreceptors) terminate in the mucosa of the nasal cavity detecting fragrances and relaying these signals to by way of the hypothalamus to the temporal lobes.

### The Vomeronasal Organ

As an interesting note, the **vomeronasal organ** (VNO) has been recognized as an intricate part of **olfaction** found in many mammals, including humans (at right). It is located adjacent to the **vomer** and **nasal** bones.

Sensory neurons in the VNO detect chemical stimuli such as **pheromones**, which are chemical signal molecules transmitted between two individuals, so the signal travels outside the body and is received in this organ located in the nose. Once received, these signals can be projected to several areas of the brain, including the **amygdala** and the **hypothalamus**. A function of the VNO is to detect 'scents' that most often are below conscious threshold, i.e., cannot be detected (smelled) in terms of conscious perception. However, these stimuli can act as communication signals and are hypothesized to influence behavior such as attraction and even aggression between individuals.



The respiratory tract is partitioned in a number of ways, as dictated by the location of the structures, or the primary function of that region, as discussed below.



### The Respiratory Tract Divisions into Upper and Lower Tracts

**Upper Respiratory Tract** – nose, nasal cavity, paranasal sinuses, nasopharynx, oropharynx and laryngopharynx are all a part of the upper respiratory tract.

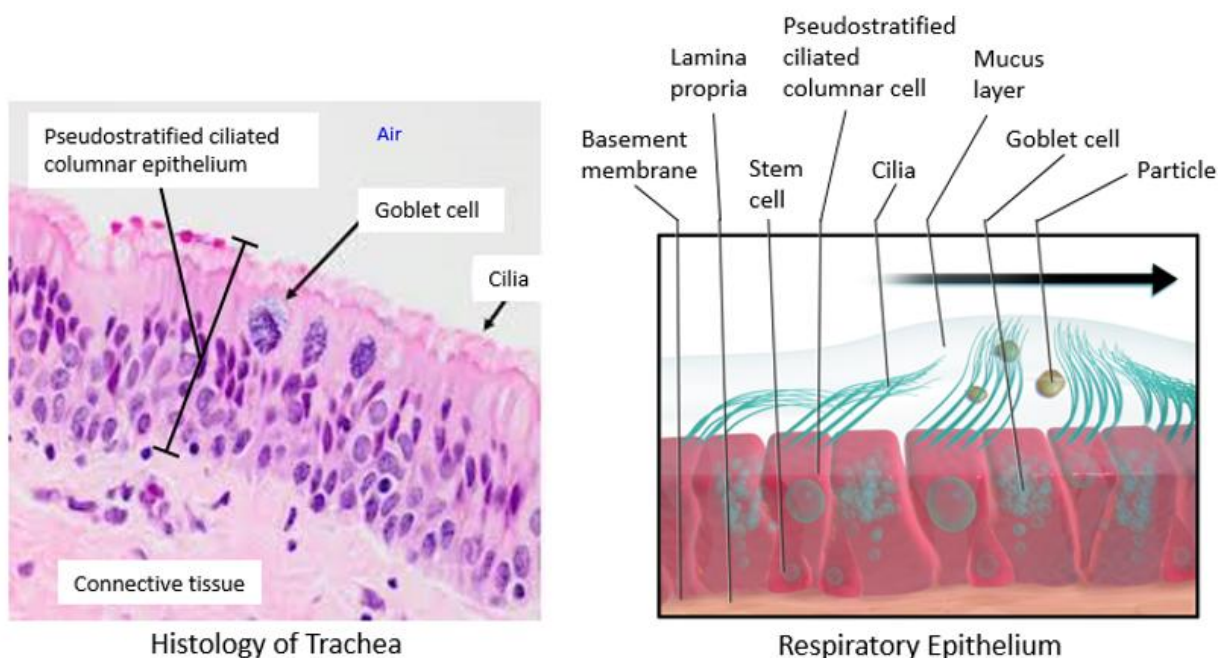
**Lower Respiratory Tract** – larynx, trachea, primary (1°) bronchi, 2° bronchi, 3° bronchi, bronchioles, terminal bronchioles, respiratory bronchioles, alveolar ducts, alveolar sacs and alveoli.

### Respiratory Tract Zones – Describe the primary Function of these Areas

- 1) **Conduction Zone:** This zone or region of the respiratory tract is for the conduction of air to and from the lungs. It starts from the **nose** and ends at the **terminal bronchioles**. The name terminal bronchioles is to signify that this region is the end (terminus) of the conduction zone.
- 2) **Respiratory Zone:** This zone or region of the respiratory tract is where gas exchange begins. This zone starts from **respiratory bronchioles** and ends at the **alveoli**. The way that the inner epithelial lining changes in this zone is indicative of its role to maximize gas exchange.

### The Lining of the Respiratory Tract

Most of the respiratory tract is lined with “**Respiratory Epithelium**” which is composed of **Pseudostratified Ciliated Columnar** (PSCC) epithelium and a lamina propria made of areolar connective tissue, see the histology (left) and drawing (right) of this arrangement. This lining is to **protect** the respiratory tract. The mucous secreting goblet cells are a component of this lining and the thick sticky mucus secretions delivered to the surface act to trap any inhaled debris or particles in the airway. Additionally, the cilia (meaning ‘hair’) on the exposed surface of the respiratory epithelium are constantly moving this mucus up the “*mucus escalator*” for expulsion from the respiratory tract. This lining does not exist everywhere in the respiratory tract, there are important exceptions (see next page).



### Important Exceptions to the Respiratory Epithelium

The term respiratory epithelium means pseudostratified ciliate columnar epithelium, however, it is very important to know the specific locations where this respiratory epithelium exists and where it changes, as it signifies a change in function of that region of the respiratory tract.

- 1) There are portions of the upper respiratory tract that are shared passageways with the digestive tract. The two regions are the **oropharynx** and **laryngopharynx**. Since both air and food travel on top of these two regions, the epithelial lining here is **stratified squamous** (non-keratinized) for additional protection. The respiratory epithelium resumes in the larynx and downward.
- 2) At the start of the respiratory zone, the function of the lining of the respiratory tract begins to change in order to become optimized for gas exchange by becoming thinner, and allowing a greater degree of exchange to occur. As such, at the **respiratory bronchioles** the respiratory epithelium changes from pseudostratified ciliated columnar epithelium to **simple cuboidal epithelium**. These cells are often ciliated cuboidal. The shorter, flatter cells here can begin to participate in gas exchange. The **alveolar ducts** are also lined with **simple cuboidal epithelium**, and as they enter and become the **alveoli**, the lining changes to **simple squamous epithelium**, as flat as it can get, to maximize gas exchange in the alveolus.

### Detailed Examination of the Respiratory Tract

#### 1. The Nose and Nasal Cavity

The beginning of the respiratory system is the nose. The **external nares** (nostrils) are the first port of entry and port of exit of air from the body. Nose hairs and the mucus lining filter inspired air. Bones and cartilage support the nose. The **nasal cavity** is a hollow space posterior to the nose that is divided into left and right portions by the bony nasal septum - made by the perpendicular plate of the ethmoid (superiorly) and the vomer (inferiorly). The anterior portion of the septum is composed of hyaline cartilage, as is the nose. The skeletons you seen in class are bone tissue only, so this cartilage tissue does not remain, hence the lack of a 'nose' on the bony skull.

Each nasal cavity (right and left) has three mucosa-covered structures called the **superior, middle, and inferior conchae** – you remember those 'shell-like' structures from the skeletal system? These used to be called the turbinate bones because they create 3 conchae meatuses (canals) which are narrow passageways in the nasal cavity that the air must travel through. These conchae therefore create turbulent air flow through the nasal cavity which significantly slows the air flow down in this region. This is important because the slowing the air flow here allows for most of the conditioning of inspired air to occur in the nasal cavity (discussed below). Breathing properly (through the nose) is more difficult than being a mouth breather, due to the much slower air flow created by the conchae, this is key to effectively conditioning the inspired air.

The nasal cavities are primarily lined with **ciliated pseudostratified columnar epithelium**, which is called 'respiratory epithelium' and contains goblet cells. This lining secretes mucus to trap particles, and these are then moved by the cilia toward the pharynx, where the particles and mucus can be removed by swallowing, sneezing, or spitting! The 4 paranasal sinuses, which surround and drain into the nasal cavities, are located in the frontal, sphenoid, ethmoid and maxillary bones.

### Inspired Air is Conditioned in 3 Ways:

- 1) It is **humidified** (water vapor added) – this improves gas exchange at the alveoli.
- 2) It is **warmed** to body temperature, if the ambient is lower than 98° F.
- 3) It is **filtered** of debris and particles by the sticky mucus lining and cilia present.

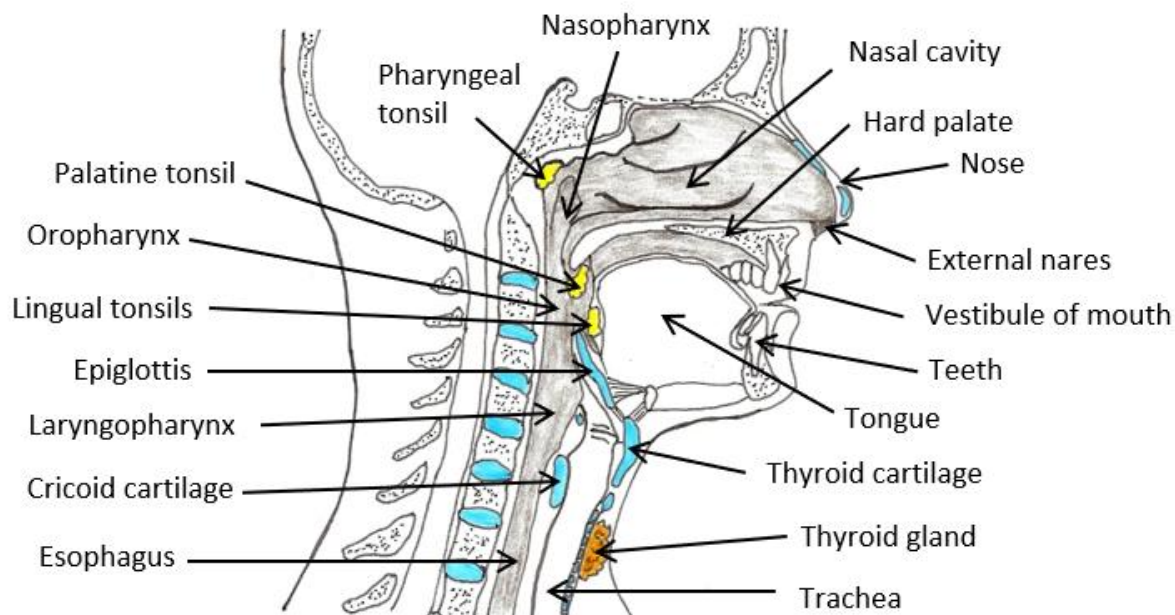
The conditioning of air is sneaky, like a cat.



### 2. Pharynx

The pharynx is the 'throat' as is composed of three regions: **1) the Nasopharynx**, **2) the Oropharynx**, and **3) the Laryngopharynx**. The nasopharynx is a passageway for air only, however, the oropharynx and laryngopharynx are shared passageways for air and food. These regions can also function in speech, changing shape to allow phonation of vowel sounds. The entire pharynx is composed of striated muscle and lined with mucous membrane. The regions of the pharynx which are shared passageways are lined with stratified squamous epithelium for protection.

### Structures of the Upper Respiratory Tract



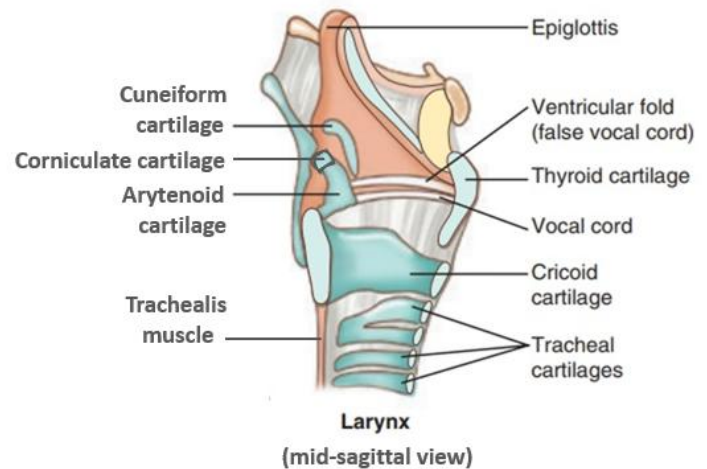
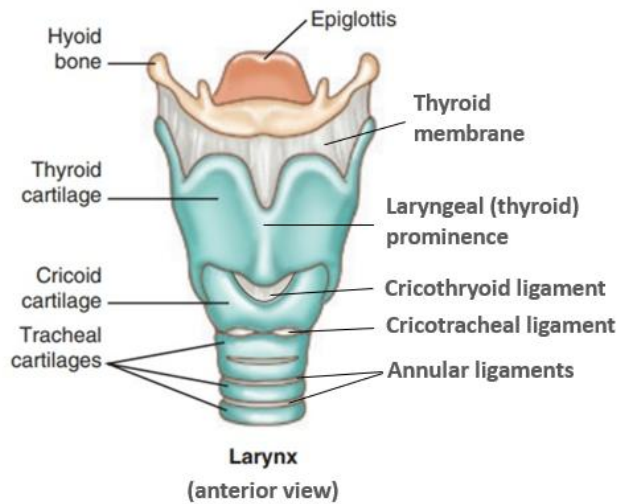
### 3. Larynx

The larynx is the 'voice box' and it extends from the 4<sup>th</sup> to the 6<sup>th</sup> cervical vertebrae, attaching to the hyoid bone. It is created by 3 large unpaired cartilages; the **thyroid cartilage**, the **cricoid cartilage** and the **epiglottis**. These function to protect the vocal folds. The thyroid and cricoid cartilages are made of hyaline cartilage, and the epiglottis is made of elastic cartilage.

The larynx also contains 3 small paired cartilages; the **arytenoid cartilages**, the **corniculate cartilages** and the **cuneiform cartilages**. These function to control and operate the vocal folds. The true vocal folds (cords) are a pair of horizontal folds of elastic connective tissue that project into the laryngeal cavity. The space between the vocal folds and the area above them within the middle of the larynx is called the **glottis**. The epiglottis, which overhangs the larynx, prevents food or fluids from entering the airways toward the lungs. The arytenoid cartilages are made mostly of hyaline cartilage with a portion of the vocal fold process made from elastic cartilage, and the cuneiforms and corniculate are made of elastic cartilage.



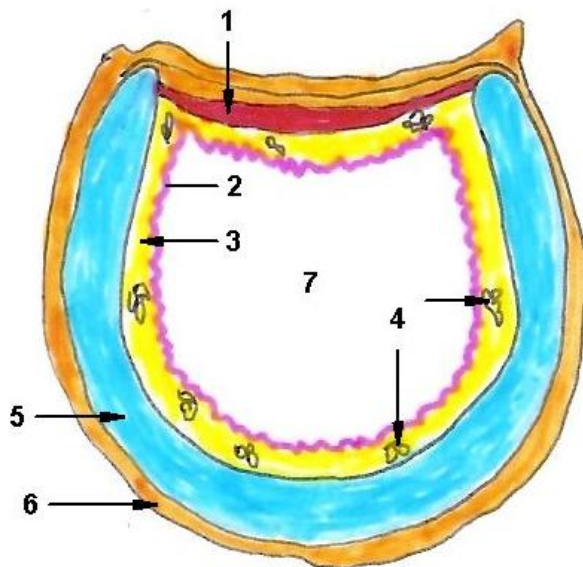
## The Larynx (voice box) from an anterior and mid-sagittal view



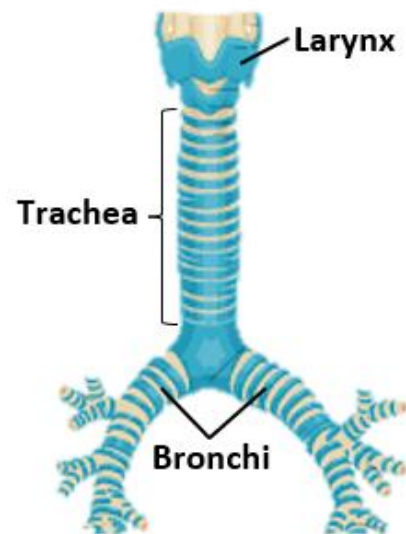
### 4. Trachea

The trachea is the 'windpipe' and is made of 16 to 20 C-shaped hyaline cartilage rings to prevent it from collapsing during inspiration and expiration. Note, none of the tracheal rings go completely around (see image below left), that is why they are called "C-shaped" rings. It is about 4 to 5 inches long and about 1 inch in diameter. Upon entering deeper into the mediastinum, it branches into the right and left primary bronchi (see image below on right) at the 5<sup>th</sup> thoracic vertebra.

#### Histological drawing of Trachea (x.s.)



1. Trachealis muscle
2. PSCC epithelium
3. Lamina propria
4. Tracheal glands
5. Hyaline cartilage
6. Adventitia
7. Lumen of trachea



Posteriorly, where there is no cartilage in the trachea, there is smooth muscle tissue called the trachealis. The esophagus is immediately posterior to the trachea and the trachealis allows for the expansion of the esophagus when swallowing a bolus of food or liquid. That is why it is sometimes harder to breathe when you are trying to swallow a whole bunch of quinoa. The trachea is lined with **respiratory epithelium** (PSCC) to filter and trap inhaled debris for removal through coughing; there is also an automated cough reflex that is triggered by

particles sticking to the mucus and cilia on the inner surface of the trachea.

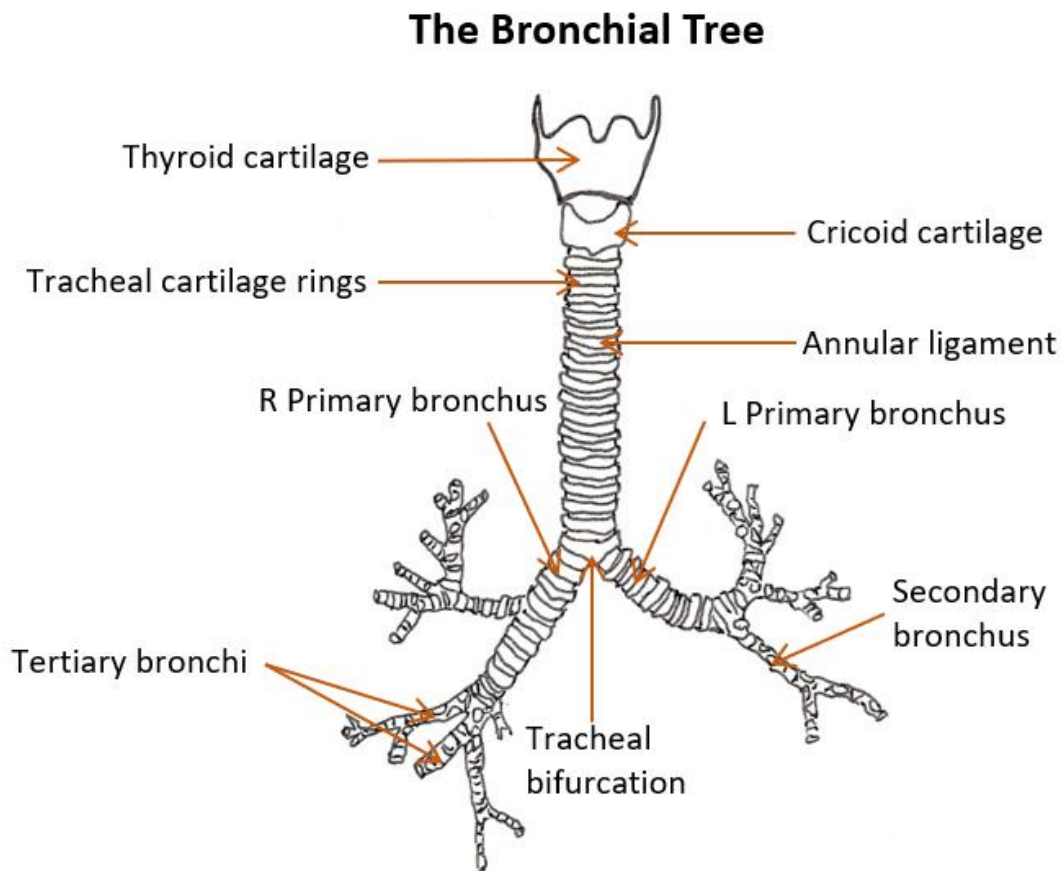
## 5. Bronchial Tree

The trachea branches into the right and left primary bronchi, and these enter the right and left lungs respectively. The bronchi branch into progressively smaller and more numerous airways until they get to the alveoli – this is the end of the respiratory tract and the smallest structure of the respiratory airway where gas exchange occurs with the cardiovascular system.

### From the Top to the Bottom:

Right & Left Primary Bronchus => secondary bronchi => tertiary bronchi => bronchioles => terminal bronchioles => respiratory bronchioles => alveolar ducts, which terminate in clusters called alveoli. Alveoli are tiny air sacs lined with thin squamous epithelium. They are 90% surrounded by capillaries where O<sub>2</sub> and CO<sub>2</sub> are exchanged.

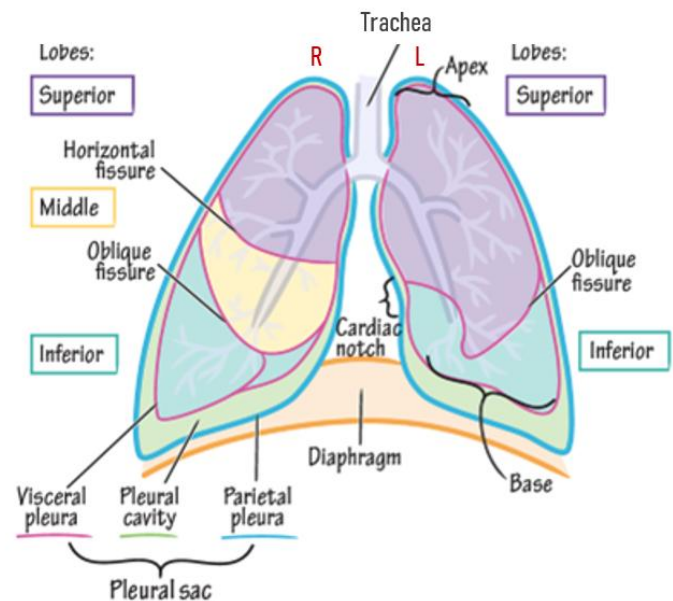
From the Left and Right **1° bronchi**, the **2° bronchi** are smaller passageways that branch from the primary bronchi. The right 1° bronchus divides into three 2° bronchi (because there are 3 lobes in the R lung) and the left 1° bronchus divides into two 2° bronchi (because there are 2 lobes in the L lung). The 2° bronchi branch into **3° bronchi** which then branch into smaller **bronchioles**. At the bronchioles the hyaline cartilage plates that were present in the 3° bronchi are now gone, and the bronchioles are now composed of respiratory epithelium on the inner lining and have a thick outer layer of smooth muscle that can constrict and dilate the bronchiole, which significant changes the air flow through these airways. The autonomic nervous system (**ANS**) changes bronchiole diameter, with parasympathetic division constricting the diameter (↓ air flow) and the sympathetic division dilating diameter (↑ air flow). The bronchioles provide the greatest resistance to air flow in the conducting division.



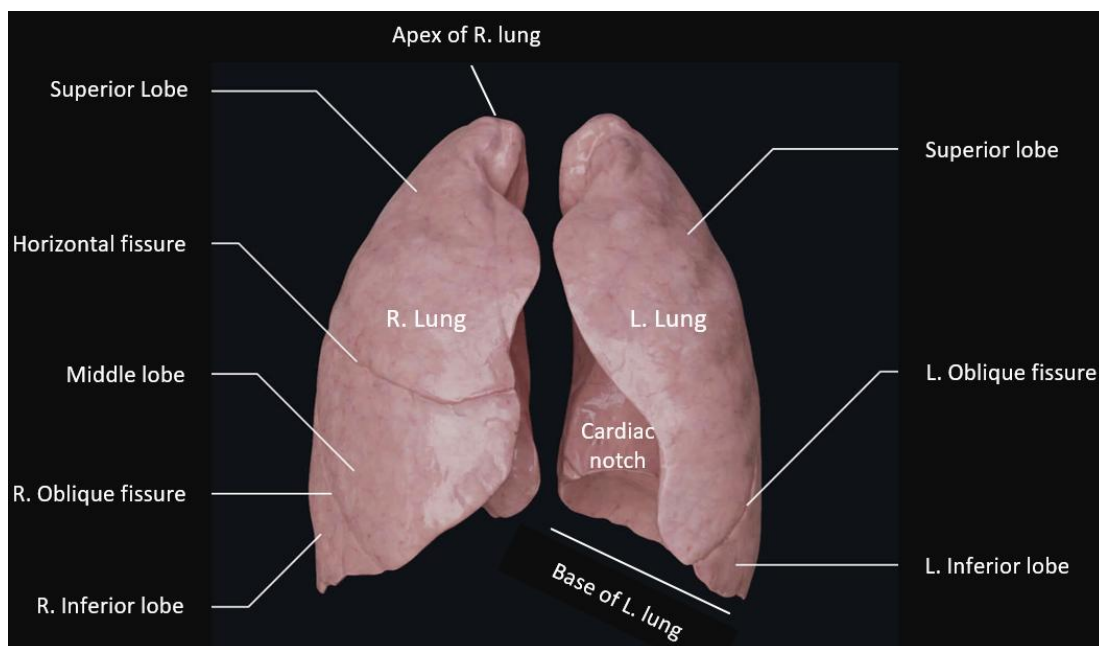
The bronchioles branch into smaller **terminal bronchioles**, which represent the 'end' of the conduction zone of the respiratory tract. These then branch into smaller **respiratory bronchioles**, which represent the 'start' of the respiratory zone of the respiratory tract. This is where the inner lining begins to change from respiratory epithelium (PSCC) into simple cuboidal epithelium, allowing for actual gas exchange to begin to occur through the thinner lining. The last section of the airways are the **alveolar ducts** leading to the **alveolar sacs** which contain many individual **alveoli**. The lining in the alveolus is now simple squamous epithelium, the flattened lining which is ideal for gas exchange.

## 7. The Lungs

The Lungs are soft and spongy cone-shaped organs that occupy the **pleural cavity** within the thoracic cavity. They extend from the root of the neck to the diaphragm. The **right** and **left lungs** are separated by the heart and other **mediastinal** structures. Recall that the lungs are contained inside a 'bag' called the **pleural sac** lined with serous (watery) membranes in order to reduce the friction between two surfaces that are constantly moving across each other. The **parietal pleura** lines the wall or the inner portion of the bag and the **visceral pleura** covers the superficial surface of the lungs as an organ (see right). The space in between the two membranes contains pleural fluid, which lubricates the lungs as they continuously move during the expansion and contraction of breathing.



The **Right Lung** is larger than left, and has **3 lobes**. The **Left Lung** is smaller (because of the cardiac notch), and has only **2 lobes**: 'Tri before you bi'. The right lung has 2 fissures; the oblique fissure, separating the superior and middle lobes, and the horizontal fissure, separating the middle and inferior lobes (see below). The left lobe has only one oblique fissure which separates the superior and inferior lobes of the left lung.



**Blood Supply to Lungs:** Blood circulates through the lungs via the pulmonary and systemic circuits.

The **pulmonary circuit** is for the delivery of O<sub>2</sub> poor and CO<sub>2</sub> rich blood to the alveoli for exchange! The pulmonary trunk arising from the right ventricle branches into the right and left pulmonary arteries, then branches into a profuse network of pulmonary capillaries which surround each alveolus. The interface between the alveoli and the pulmonary capillaries is where O<sub>2</sub> from the alveoli diffuses into the capillary and turn the **blue** blood **red** when it binds with hemoglobin (Hb) inside the red blood cells. At the same time, the CO<sub>2</sub> in the blood diffuses from the blood into the air-filled alveolus and is exhaled!

The **systemic circuit** delivers O<sub>2</sub> and nutrient rich blood to the lung tissues by way of the bronchial arteries, which branch off of the thoracic aorta. This circuit does deliver O<sub>2</sub> and pick up CO<sub>2</sub> with lung tissue but has nothing to do with exchanging gases with alveoli!

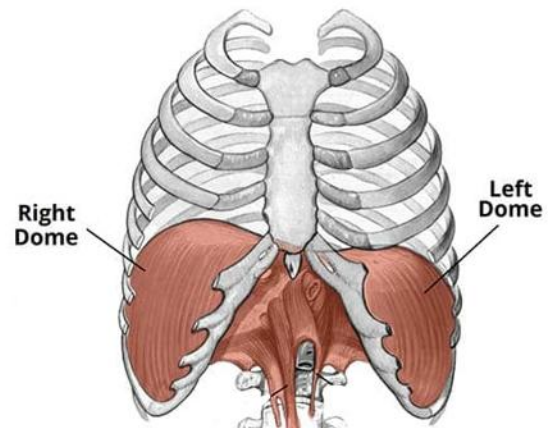
### Skeletal Muscles Involved in Breathing

Breathing is accomplished by changing the volume of the thoracic cavity, which inversely changes the pressure of the cavity and we either breathe air in or out!

Muscles that expand the thoracic cavity are **inspiratory** muscles and muscles that compress the thoracic cavity are **expiratory** muscles. Another important component of breathing to keep in mind is elasticity. Since each alveolus is covered extensively with elastic fibers this elastic recoil allows the lungs expel air without any muscular contraction at rest.

### The Diaphragm

The principal muscle of inspiration is the diaphragm (see right), the large domed-shaped skeletal muscle separating the thoracic and abdominal cavities. When the diaphragm contracts both the right and left domes flatten, moving downward into the abdominal cavity. This increases the volume of the thoracic cavity, lowering its pressure, allowing air to flow down its pressure gradient from the outside into the lower pressure lungs, akin to air being sucked into lungs!



**Eupnea** = Quiet breathing. The 'eu' means true and the 'pnea' means breathing, so this is the breathing that is taking place most of the time when you are at rest, or doing low level activities.

### Muscles Required in Eupnea

**Inspiration:** Contraction of the **diaphragm** – this lengthens and enlarges the thoracic cavity when it contracts; and contraction of the **external intercostals** – this expands the lateral aspects of the thoracic cavity (like the expansion from raising the handle of a bucket at the sides of the bucket). To a lesser degree, the contraction of the **scalene** and **sternocleidomastoid** muscles also accentuate inspiration because they pull at the top of the rib cage and serve to lengthen it.

**Expiration:** No muscle action required! Simply relax the muscles that were contracted that enabled us to breathe in.

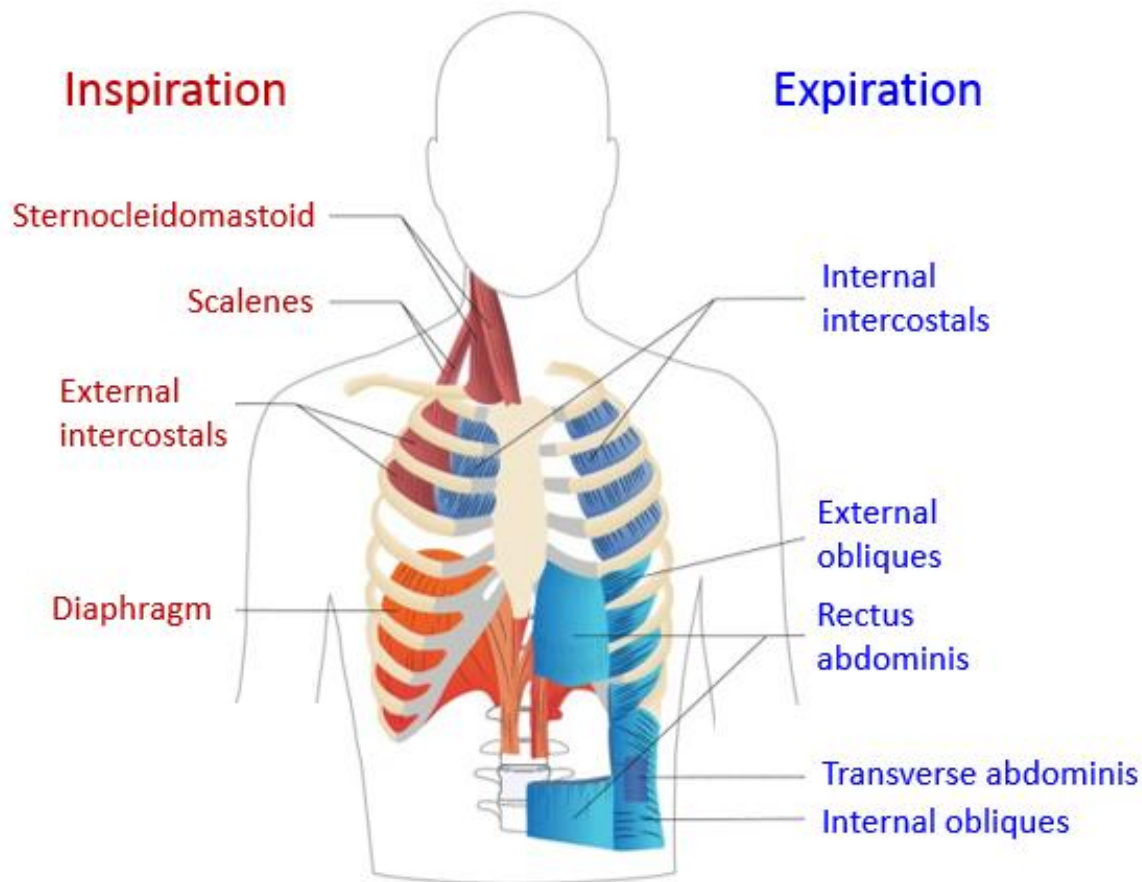


**Forced Breathing** = accelerated and deep breathing which can be due to either intense physical activity (hyper eupnea) elevating metabolic needs, or from emotional stress (hyperventilation).

#### Muscles Required in Forced Breathing

**Inspiration:** **diaphragm**, **external intercostals**, **scalenes** and **sternocleidomastoids**. All more forcefully.

**Expiration:** **Internal intercostals** and the 4 abdominal muscles => **rectus abdominis**, **transverse abdominis** and the **internal** and **external oblique** muscles.



#### **The Control of Breathing**

The two primary regions in the brain that regulate breathing are the **medulla oblongata** and the **pons**. In terms of the control of ventilation, it is an elegant combination of multiple regions in the brain that signal the muscles required for pulmonary ventilation. The result is typically a consistent, rhythmic ventilation rate that provides the body with sufficient amounts of  $O_2$ , while adequately removing and balancing the  $CO_2$  levels in the body.

In very simple terms, the medulla oblongata (MO) creates the rhythmic pace of breathing. For example, it is the phrenic nerve, that arises from the cervical plexus, which automatically and rhythmically fires to contract the diaphragm which creates the automated pace of eupnea. It is the pons that is more involved with fine tuning of ventilation, occasional changing the depth and force of breaths. The pons also plays a protective role, as it inhibits the over-inflation of the lungs, which can damage lung tissue.

The MO contains the **dorsal respiratory group (DRG)** which regulates eupnea, and the **ventral respiratory group (VRG)**, which makes adjustments for force breathing. The pontine respiratory group (in the pons) consists of two centers; the **apneustic center**, which stimulates and prolongs inspiration, and controls the **depth of inspiration**, particularly for deep breathing. The other center is the **pneumotaxic center**, which inhibits the activity of the apneustic and the DRG (inspiratory center), allowing muscle relaxation after inspiration, and therefore controlling the overall ventilation rate, and importantly, preventing the over inflation of the lungs.

It is the actions of the somatic nervous system (SNS) that carry out the efferent signals from the brainstem to the intercostal muscles, the diaphragm, and other respiratory muscles involved in ventilation. Since the somatic nervous system (SNS) controls skeletal muscle, there is also conscious control of breathing.

### Feedback Control

Sensory receptors play important roles in the regulation of respiration. There are three types of receptors in the respiratory system; central chemoreceptors, peripheral chemoreceptors, and mechanoreceptors. These receptors detect critical changes in various parameters within the respiratory system and through feedback loops make adjustments to the rate and depth of breathing in order to maintain homeostasis.

- **Central chemoreceptors** of the central nervous system are located in the **medulla oblongata**, on the ventrolateral medullary surface. These receptors are sensitive to changes in the pH ( $H^+$ ) of the cerebrospinal fluid (CSF) that bathes the brain and spinal cord. Since  $H^+$  cannot cross the protective blood brain barrier (made by astrocytes), the accumulation of  $H^+$  in the CSF signals the body to increase ventilation so that more  $CO_2$  is expelled and this restores balance via the bicarbonate buffer system briefly mentioned at the start of these notes. These receptors control the normal rhythmic pace of breathing.
- **Peripheral chemoreceptors** are strategically located in two important systemic arteries: 1) the **carotids sinuses** (blood going to brain); and 2) the **aortic arch** (blood going to body). Here they detect variations in the  **$CO_2$ ,  $H^+$  (pH) and  $O_2$**  levels in the arterial blood in that order. In terms of sensitivity. They also signal the medulla oblongata to change the pace of breathing.
- **Mechanoreceptors** are located in the airways and in actual lung tissue and are responsible for a variety of protective reflex responses, including preventing the over-inflation of lungs. The upper airway receptors are responsible for reflexes such as, sneezing, coughing, closure of glottis, and hiccups.

### Voluntary Control of Respiration

Respiration can also be affected by emotional states, the ambient temperature, and even free will. These factors involve input from the limbic system, also known as the emotional brain, and other 'higher' brain regions, such as the cerebral cortex, where conscious voluntary actions are planned out. Therefore, the control of breathing is not solely the purview of the pons and medulla oblongata, it can be modified by a person's emotional state, and further, a person can create voluntary or conscious control of breathing, such as holding their breath until they get their way. Please note: The **chemoreceptor reflex** has the ability to override any of these emotional states or conscious decisions.