

Anatomy Lecture Notes Section 1: Tissue Membranes in the Body

Tissue Membranes

Within the body there are many structures called **membranes**. In terms of naming the various membranes in the body, it is necessary to recognize the specific tissues involved, the function of it as a structure, and the location of the membrane in the body. The focus in these notes at this point is the **epithelial tissue membranes**.

In general, tissue membranes are usually made up of thin layers of cellular tissue that cover exposed body surfaces, line internal body cavities, or cover organs within the cavities in hollow organs. Tissue membranes can be categorized into **epithelial** and **connective** tissue membranes.

Epithelial Membranes

Epithelial membranes consist of **epithelial tissue** (on the top or at the exposed or apical end), and **connective tissue** below, to which it is attached by way of the basement membrane. There are two “wet” types of epithelial membranes, called mucous membranes and serous membranes. There is also a “dry” epithelial membrane called the cutaneous membrane (skin). They all follow this basic pattern:

$$\text{Membranes in Anatomy} = \frac{\text{Epithelial Tissue}}{\text{Connective Tissue}}$$

The 3 types of Epithelial Membranes:

1. **Mucous membranes** – These membranes line the body passageways or tracts that are exposed to the outside environment. They are “wet” membranes, having a mucus secretion for protection and hydration.
2. **Serous membranes** – These line internal body cavities that are not open to the external environment. They are also a “wet” membrane, having a serous (watery) secretion for the main purpose of reducing friction between two surfaces that are constantly moving across each other.
3. **Cutaneous membranes** – This covers the entire outermost surface of the body. It is the only “dry” membrane encountered in the body and an important role is the prevention of water loss from the body. It is also a physical barrier and protective to deeper tissues. This membrane is also called the skin.

All of the epithelial membranes listed above will have some type of epithelial tissue on the top (like the formula above), and the supporting connective tissue immediately deep to it. Now let’s look at the specific details for each of the three types of epithelial membranes.

1. Mucous Membranes

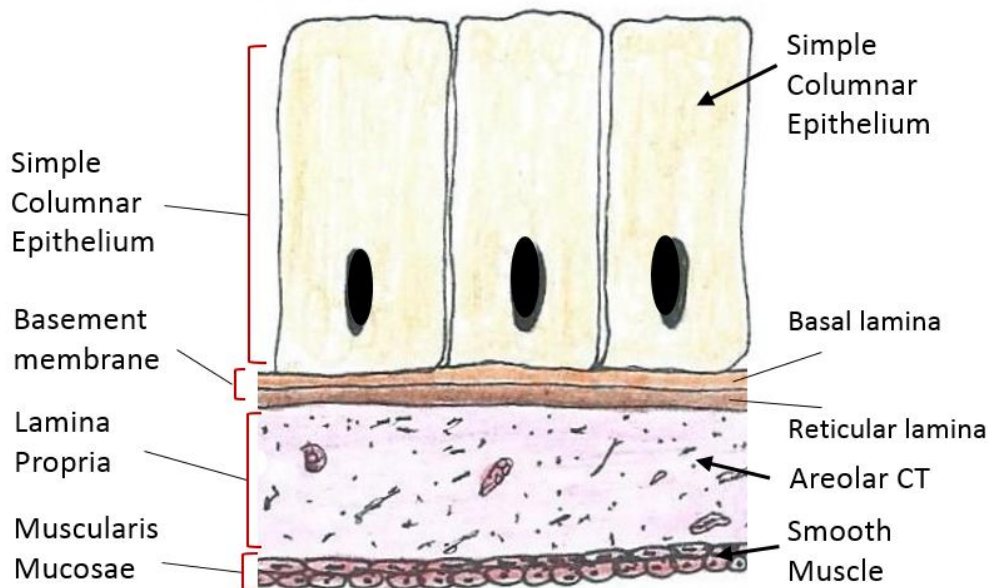
Mucous membranes are epithelial membranes that consist of epithelial tissue that is attached to an underlying loose connective tissue. There is often a third layer to the mucous membrane it is made out of smooth muscle is called the ‘Muscularis Mucosae’.

These membranes, sometimes called *mucosae*, line the body cavities that technically are directly open to the outside. This includes the entire **digestive (gastrointestinal) tract** - it is all lined with mucous membranes. Other examples of where mucous membranes are found in the body include the **respiratory tract**, the **urinary tract**, and the male and female **reproductive tracts**.

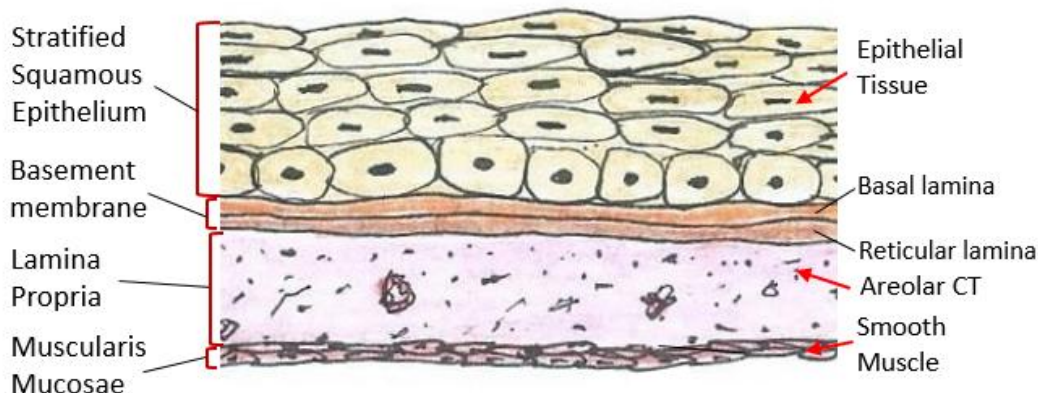
The function of the mucous membrane can vary, but its roles include:

- **Protection** – of the deeper tissues and the entire body. *Usually has *stratified* epithelium.
- **Absorption** – of substances across the membrane. *Usually has *simple* epithelium.
- **Secretion** – of substances for various purposes in the body.

Examples of Mucous Membranes



The above drawing shows a classic type of mucous membrane found in many regions of the body. The epithelial portion of the membrane is **simple** (only one cell layer thick) columnar (it's taller than it is wide). If the epithelial portion is simple, it usually means that a primary role of this membrane is absorption, as one cell layer is much easier to get across than multiple cell layers. The **columnar** cells give more protection and is found in the stomach, small and large intestines for example. Absorption is a role, but so is protection. Other mucous membranes with shorter cells like a **cuboidal** or **squamous** cells are for fast absorption and can be found in the respiratory tract where rapid gas exchange becomes vital.



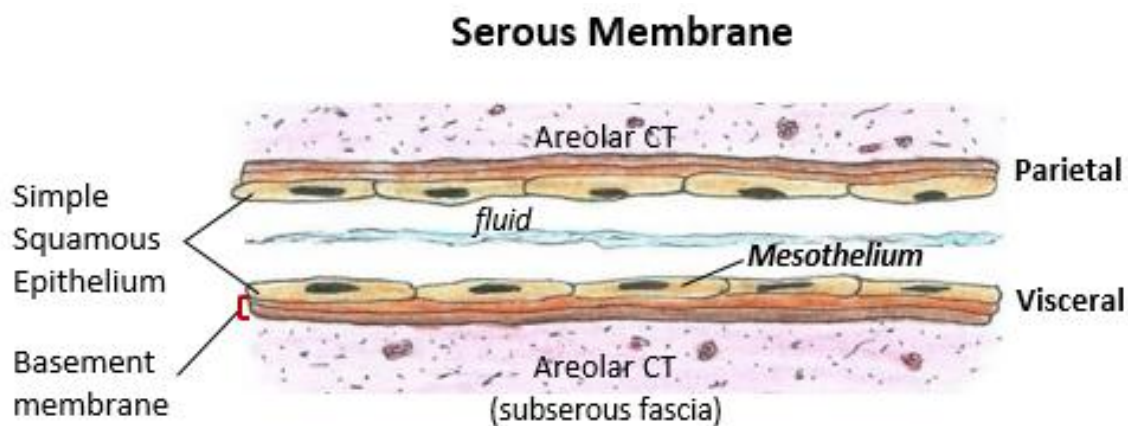
Here is another example of a mucous membrane, now epithelial portion of the membrane is stratified (many cell layers thick) squamous (very flat at the apical end). Thus, its main function is **protection**. This type of mucous membrane is found in the **oral cavity** (mouth), **esophagus**, anal canal and the **vaginal canal**. Mucus, produced by the epithelial exocrine glands, covers the epithelial layer. The underlying connective tissue, called the **lamina propria**, (meaning layer of my own) helps support and nourish the

avascular epithelial tissue. The deepest portion of this membrane is called the **muscularis mucosae**, which is composed of two very thin layers of smooth muscle orientated perpendicular to each other. This structure helps to provide limited local movement of the tissue in specific regional areas.

2. Serous Membranes

Serous membranes line body cavities that do not open directly to the outside environment. These membranes **line internal body cavities** and they also **cover the organs located in those cavities**. Serous membranes are wet or moist membranes and are always covered on their surface by a thin layer of thin **serous fluid** which is watery and slippery, that is secreted by the epithelium of the membrane.

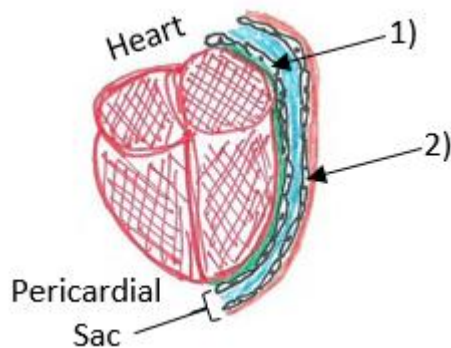
All serous membranes secrete serous fluid, and this thin watery fluid **lubricates** the membrane surface and **reduces friction** and **abrasions** when the organs (**viscera**) that are covered by them move across the surface of the walls (**parietal**) that are directly surrounding them.



The serous membrane in the drawing above is composed of epithelium which is *always* **simple squamous** epithelium attached to a thin layer of connective tissue, which is *always* **areolar connective tissue**. Any serous membrane will always have two components: One component covers the outermost surface of the organ and is called the **visceral layer**. The other component covers the inner lining of the bag or the cavity, and it is called the **parietal layer**.

Serous membranes have special names given to them according to their location, meaning which cavity they are in, and also for which of the two surfaces they are covering – the organ = visceral and the wall around the organ = parietal.

For example, within the thoracic cavity there are other cavities, such as the **pericardial cavity** (meaning around 'peri', the heart 'cardium'). The pericardial cavity contains the heart. As seen in the drawing below, the outermost surface of the heart (which is an organ!) has a serous membrane, labeled **1)** that is the



visceral pericardium. The pericardial sac is the bag (or wall) around the heart also has a serous membrane on its inner surface labeled **2)** that is the **parietal pericardium**.

Here are the other examples of serous membranes:

There are the two pleural cavities which each contain one lung. The outermost surface of the lung is called **visceral pleura**, and the inner surface of the bag around it is called the **parietal pleural**.

In the abdominopelvic cavity, all of the organs there move against each other in the peritoneal cavity. The outermost surface of those organs is called the **visceral peritoneum** and the 'wall' of that cavity is called the **parietal peritoneum**. A serous membrane is an epithelial membrane composed of mesodermally-derived epithelium called the **mesothelium** that is supported by connective tissue. These membranes line the coelomic cavities of the body, which means that they cover the organs located within the cavities **that do not open to the outside**.

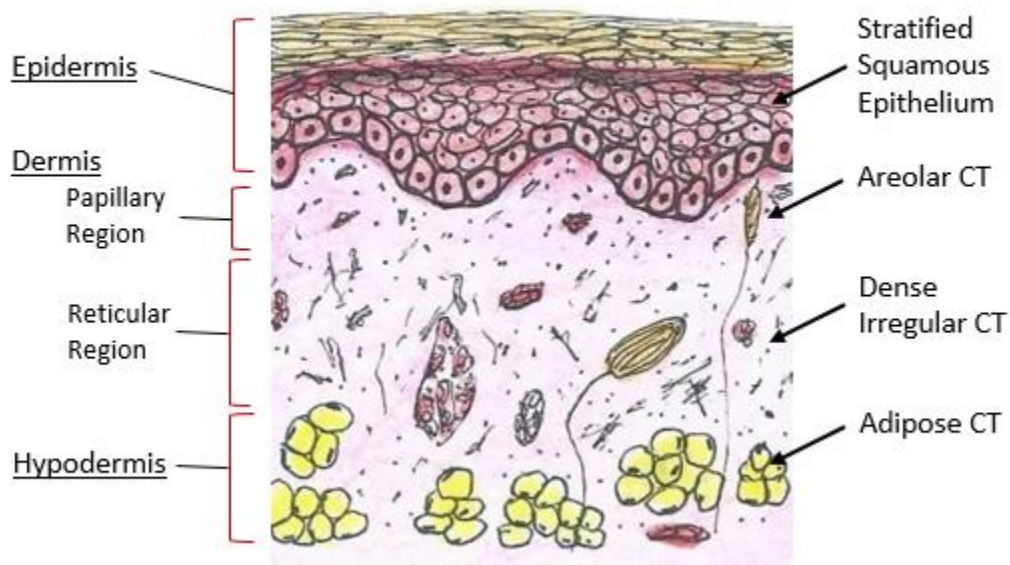
Serous fluid secreted by the cells of the thin squamous mesothelium lubricates the membrane and reduces abrasion and friction between organs. Three serous membranes line the thoracic cavity; the two pleura that cover the lungs, and the pericardium that covers the heart. A fourth, the peritoneum, is the serous membrane in the abdominal cavity that covers abdominal organs and forms double sheets of mesenteries that suspend many of the digestive organs.

3. Cutaneous Membranes

The skin, also called the cutaneous membrane, is also an epithelial membrane. The skin is a stratified squamous epithelial membrane resting on top of connective tissue. The apical surface of this membrane is exposed to the external environment and is covered with dead, keratinized cells that help protect the body from desiccation and pathogens.

The layers of the skin that constitute the cutaneous membrane are the **epidermis**, which is the outer layer composed of the epithelial tissues, and the **dermis**, which is the inner layer composed of the connective tissues. One of the primary roles of this membrane is to help protect the rest of the body's tissues and organs from physical damage such as abrasions.

External Exposed Surface



As seen in the drawing above, the cutaneous membrane is composed of a **stratified squamous epithelial tissue** (that is keratinized or dry) sitting upon first **areolar connective tissue** (the superficial connective tissue layer) and then **dense irregular connective tissue** (the deeper connective tissue). In the cutaneous membrane, the epithelial tissue is called the **epidermis**, and the entire connective tissue is called the **dermis**. Deep to the dermis is the **hypodermis** layer, and this is not technically considered a part of the cutaneous membrane. The hypodermis, which consists mostly of adipose (fat) tissue, is also a type of fascia, it is called **superficial fascia**, which gives support to the cutaneous membrane above it.

Cutaneous is from the Latin 'cutis' which means 'of the skin'. This membrane, also called the **skin**, has an important role in protection of the body against trauma and also prevents excessive water loss. It has many other functions which will be covered in depth in the lecture notes for the **Integumentary System** that it is a central part of. Briefly the skin provides effective insulation, temperature regulation, provides sensory input (sensations), and the epidermis of the cutaneous membrane initiates the synthesis of vitamin D.

Connective Tissue Membranes

Connective tissue membranes contain only connective tissue, **synovial membranes** and **meninges** belong to this category. Synovial membranes will be examined in more detail in the articulations section. The meninges (cranial and spinal) will be discussed further in the nervous system section of this course.

The connective tissue membranes are formed solely from connective tissue. These membranes encapsulate organs, such as the kidneys, and line our movable joints.

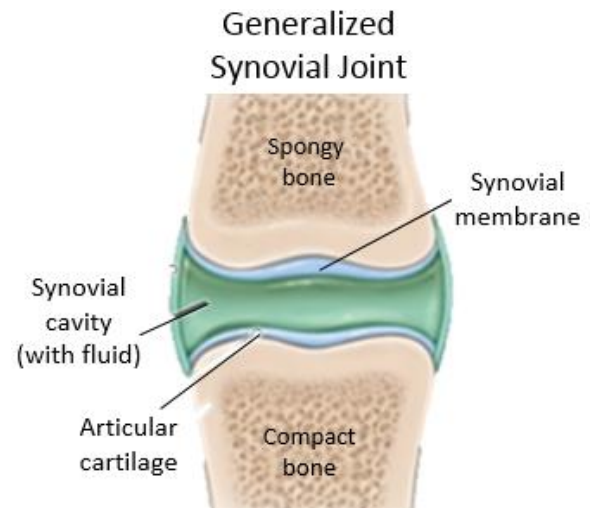
Synovial Membranes

Synovial membranes are connective tissue membranes that line the cavities of the freely movable joints such as the shoulder, elbow, and knee. In the articulation (joint) system, we will more closely examine synovial membranes.

Within the membrane are found fibroblast-like cells called 'synoviocytes' that sit on the inner layer of the synovial membrane. They release hyaluronan, also called **hyaluronic acid**, into the joint cavity. The hyaluronic acid effectively traps available water within the joint capsule to form this slippery viscous substance called **synovial fluid**, a natural lubricant that enables the bones of a joint to move freely against one another without much friction.

Synovial fluid is an important body fluid as it readily exchanges water, nutrients and gases between the cartilage and the blood. It also acts as a lubricant at the movable articulation, as well as a hydraulic cushion.

Like serous membranes, synovial membranes line cavities that **do not open to the outside environment**. However, unlike serous membranes, they do not have a layer of epithelium, instead they have a layer of connective tissue cells that perform similar functions. As mentioned above, synovial membranes secrete synovial fluid into the joint cavity, and this nourishes, protects and lubricates the articular cartilage on the ends of the articulating bones so that they can function properly and provide ease of movement.



The Meninges

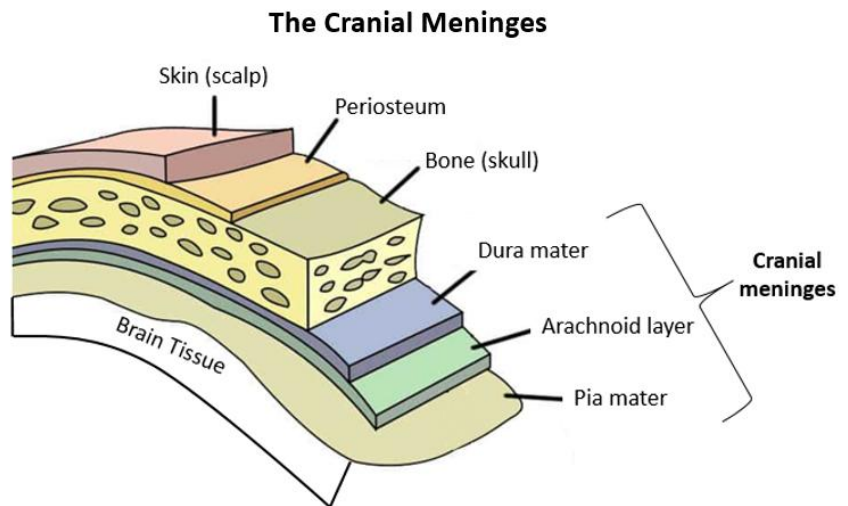
Another type of connective tissue membrane that acts as a covering of delicate nervous tissue are called the meninges. The protective covering of the brain is called the **cranial meninges**, and the protective covering of the spinal cord is called the **spinal meninges**.

Both of these meninges are located within the cranial and spinal cavities respectively, which are located within the larger dorsal cavity. The primary role of the meninges is to provide protection of the brain and spinal cord, as these are vital and relative delicate structures.

Three layers of membranes known as meninges act to protect the brain and spinal cord (shown on next page). The three layers from outermost (superficial) to innermost (deep) are as follows:

- 1) the **dura mater** is the thick, tough fibrous outer layer of the meninges (dura means tough and mater means mother);
- 2) the **arachnoid** is the middle layer of the meninges and is a web-like structure, that has a space below that is filled with cerebrospinal fluid (CSF) that cushions the brain;
- 3) the **pia mater** is the most delicate and thinnest tissue, and the innermost layer that covers the nervous tissue and follows its contours.

The meninges function to protect the central nervous system (CNS) from trauma or injury to the brain or spinal cord, such as a blow to the head, or taking a tumble, by acting as a shock absorber. They also anchor the CNS, like a seat belt is clipped in to restrict movement, the meninges keep the brain and spinal cord from moving around within the skull or spinal column.



The illustration on the previous page shows the meninges (singular **meninx**), the specific example displayed depicts the **cranial meninges**. The illustration below shows the spinal meninges, and as we will see in the nervous system section as we analyze the anatomy more thoroughly, the cranial and spinal meninges have slightly different arrangements, creating very important differences.

Note the three-layered membranous envelope that are all deep to the bone (the skull or the vertebrae) for both the cranial and spinal meninges. The meninges are always composed of the outer dura mater, the middle arachnoid layer, and the inner pia mater. This membrane completely surrounds the brain and spinal cord. Contained within the membrane, specifically within the space between the pia mater and the arachnoid (called the **subarachnoid space**) is cerebrospinal fluid (CSF), it is circulated throughout the CNS. In addition, the CSF also fills the **ventricles** of the brain and the **central canal** of the spinal cord.

