

Anatomy Lecture Notes Section 1: Introduction to Anatomy

What is Human Anatomy?

Human anatomy is the study of the **structures** of the human body. The discipline of human anatomy involves the identification and description of structures within the human body, including gross anatomy (examining with the unaided eye) and histology (examining tissues under a microscope).

What's in a Name? Answer: Everything.

Most anatomical names come from **Latin** and **Greek**, and these words have meaning in their original language. Therefore, it is very helpful and interesting to know the 'root' meaning and origins of these words, which is called the **etymology** of a word, as it helps in the learning process. Becoming familiar with the etymology of anatomical terms is an important component of studying human anatomy.

For example, the word **anatomy** comes from the Greek language, composed of *ana* = up or apart, and *tome* = a cutting. Therefore, the word anatomy means "cutting up or apart". In some aspects, it appears to some degree that we cut things apart as we examine each system separately.

In general, anatomy can be divided into **Gross Anatomy** and **Microscopic Anatomy**.

Gross Anatomy

In the healthcare field, gross anatomy (macroscopic) refers to the study of structures that can be seen with the naked eye, such as most bones (see image at right) and muscles. Gross anatomy may involve dissection or non-invasive methods in order to examine specific regions; the objective is to gain insight into the larger structures of organs and organ systems, how they function and how they are interconnected with other structures. To the right is an example of the gross anatomy of a bone, compared to bone tissue under a microscope after it is treated and sectioned.

Microscopic Anatomy

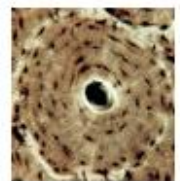
Microscopic anatomy, also known as **histology** (histo = tissue; ology = study), is the study of tissues that are too small to be seen with the naked eye, and therefore require the use of various **microscopes**. **Microscopy** commonly involves studying tissues and cells that have been prepared by significant histological techniques in order to provide visual contrast of the different components of the specimen under examination. Tissues are typically treated with severe preserving agents, alcohols, resin waxes and histological stains (such as **hematoxylin** and **eosin**, or H&E). These manipulations allow for the sectioning (cutting) of tissues into very thin slices, using the various staining of the specimens to enhance visual contrast. The different colors and intensities are based primarily on the chemistry of the tissue (lipid, protein, acidic, basic, etc.), and the nature of the dye. Understandably, the process of creating a histological slide will change the actual tissues that are being examined under a microscope (light or electron).

Gross Anatomy



Bone
(macroscopic)

Microscopic



Osteon
(micro-anatomy)

General Information

As mentioned, there is an emphasis in anatomy on word roots and their meanings. There are a lot of words to become familiar with, and it is crucial to keep up with the vast vocabulary content in this course. One of the best techniques is associating the root term with something that is already familiar to you. For example, the prefix **hypo** means below or under, and the term **chondro** is associated with cartilage (part of the ribs are made of cartilage). Thus, the term **hypochondral** refers to an anatomical region of the body 'under the ribs'. Notice when a hypochondriac (someone who frequently believes they are ill) gestures, they often wave their hands around their tummy (below the ribs) and declare they are not feeling well!

It will become very useful to relate as many anatomical structures as possible to their root words to better understand their meaning, and to facilitate remembering these names more effectively.

Grammar in Anatomy

The term grammar refers to a set of rules used to combine words for complex meaning. Grammatical constructs relate to anatomical terms, resulting in similar looking words with different endings which indicate use as nouns and adjectives, etc. For example, **cranium** is the noun and **cranial** is the adjective.

The **prefix** is at the beginning of the word and the **suffix** is at the end. These are important elements of a word to understand the full meaning. In addition, anatomy uses many diminutives – meaning a way of modifying a word to convey extreme smallness, or another quality of the object. We see this in English with cigar vs cigarette, or kitchen vs kitchenette. Diminutives also convey a sense of endearment. Abuela vs abuelita. An anatomy example is organelle, a term that means “teeny tiny little” organ structure.

Spelling in Anatomy

As the terms used in anatomy are a combination of several languages (Greek, Latin and English), there will be many terms with similar names, and this is one reason why precise spelling is important in anatomy. There are many similar terms in anatomy that refer to *different* structures, thus it is critical for us to be keenly observant of the exact name and spelling for a particular structure. Here is an example of three terms that have very similar spellings and also sound alike; **conoid**, **coronoid** and **coracoid**. Are they three names for the same structure? Negatory! Each term is for a distinctly different bony landmark on the skeleton. Sometimes students can get very creative and introduce a new term to anatomy, such as *coranacoid*. Creativity is great, though in anatomy at this stage, accuracy is paramount.



The precise nature of anatomy helps to remove ambiguity (the uncertainty of meaning) when describing a structure or location. In terms of taking care of others, especially in an emergency situation, the more certainty we have (that is, the less ambiguity), the better.

An important tip about spelling in anatomy is to learn the root meaning of the words. Create a practice of seeking to find and understand the meaning of these words, and breaking down other elements of a word that may help distinguish it from another. For example, the term **corona** means 'crown'. Coronation is the crowning of someone. The coronary circulation refers to vessels of the heart, the crown of our health!

Knowing this, let's look again at that term *coronoid* from above and see if we can distinguish it from the other terms. We can see the root **coron** in the prefix, meaning crown, and the suffix **-oid** means like or resembling. The coronoid is often a sharp protruding feature, looking somewhat like a crown.

Eponyms in Anatomy

In anatomy there are often several terms for one structure. In the past it was common to name structures after the “discoverer’s” name, these names are called “**eponyms**”. If you drive a Ford, you are driving around in an eponym! Often disorders are also named after people. For example, many know of Lou Gehrig’s disease, which is also known as amyotrophic lateral sclerosis (ALS). Currently, the more preferred terminology in medical science is that which is descriptive rather than named with an eponym.

Here is an example in anatomy: Compare **Eustachian tube** with **auditory tube**. The Italian *Eustacia* was cited as the first to describe this anatomical structure, but this name gives no indication as to its role or location. In contrast, it is likely that the word *auditory* suggests a role for this structure in sound or a location that has something to do with the ear, giving a distinct advantage to functional names.

The descriptive name can vary in its focus, ranging from describing function, location, shape, etc., and is very useful. At the same time, it is important that students become familiar with both the eponym and the descriptive anatomical terminology since eponyms are widely used.

There are many examples of eponyms in anatomy. Below is a list of a few more we will encounter, with their **eponym** first, and then the functional (descriptive) name follows with some information about it.

- **Achilles tendon** = calcaneal tendon of the heel.
- **Bowman's capsule** = glomerular capsule of the nephron in the kidney.
- **Cowper's gland** = bulbourethral gland of the male reproductive system.
- **Fallopian tubes** = uterine tubes of the female reproductive system.
- **Graafian follicle** = mature follicle of the female gamete or the egg cell.
- **Kupffer cell** = macrophages of the liver.
- **Islets of Langerhans** = pancreatic islets of the pancreas where hormones are made.
- **Meissner's corpuscle** = tactile corpuscle for touch sensation in the dermis of skin.
- **Nissl bodies** = ribosomes within nerve cell bodies.
- **Sphincter of Oddi** = hepatopancreatic sphincter to control the flow of bile and pancreatic juices.
- **Pacinian corpuscle** = lamellated corpuscle for pressure sensation deep in dermis of skin.
- **Node of Ranvier** = myelin-sheath gaps along the length of myelinated axons of neurons.
- **Canal of Schlemm** = scleral venous sinus which drains aqueous humor of the eyeball.

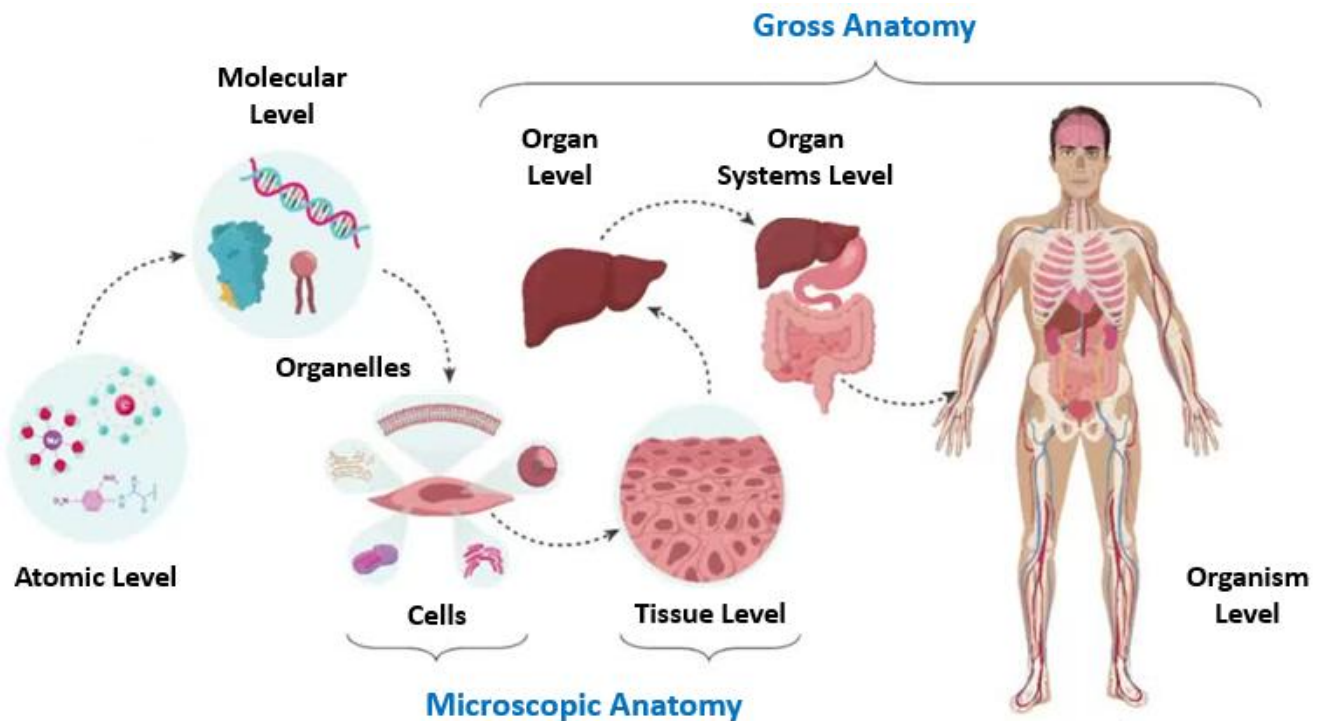
**Note that an eponym is using a proper name and thus the term must be capitalized.*

Introduction to the Study of Anatomy

Structure (anatomy) and function (physiology) are closely correlated in the human body. It is important to understand the connection between **form** and **function** when studying anatomy as the shape (form) of a structure is strongly indicative of what it does (function). This approach to the study of anatomy is called “functional anatomy”, and it is the approach that we use in this course.

I. Levels of Organization – this describes a process of examining things from simple to more complex, from the building blocks ascending to more complex and larger structures. Below are the basic levels of organization for human anatomy listed from simplest to most complex (A to H).

- | | |
|----------------------|-------------------------|
| A. Atoms | E. Tissues |
| B. Molecules | F. Organs |
| C. Organelles | G. Organ systems |
| D. Cells | H. Organism |



Any basic anatomy textbook will show this order of structures (shown above) and give specific examples of each level. This is also an example of how the course is constructed, as we go from micro-structures that we cannot see with the naked eye, to macro-structures that can easily be seen.

II. Basic Functions of Living Organisms

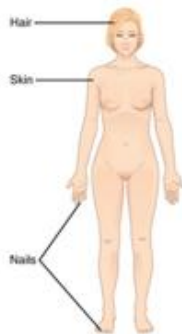
- Responsiveness
- Growth
- Differentiation
- Metabolism
- Movement
- Reproduction
- Excretion

Each system we study in human anatomy (see below) will contain various components of these functions listed above. We commence the study of human anatomy with **histology** - the study of tissues. This micro-anatomy requires the use of microscopes and the identification of the four primary tissues, and also the elements (such as cells, fibers and other material) that we can visualize in the prepared histological slides.

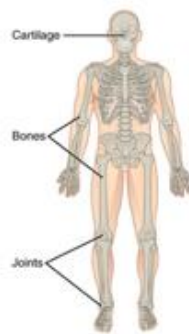
III. The Systems Studied in Anatomy – Basic Outline of the Sequences of Systems Studied

1. Tissues – four primary tissues: Epithelium; Connective; Muscular; Nervous.
2. Integumentary - skin, hair, nails and glands.
3. Skeletal - bones, cartilage, articulations.
4. Muscular - skeletal, cardiac and smooth muscles.
5. Nervous - nerves, glial cells, central nervous system (NS), peripheral NS and autonomic NS.
Special Senses - eyes, ears, touch, olfaction, equilibrium and taste.
6. Endocrine – primary and secondary endocrine glands.
7. Cardiovascular - heart, arteries, capillaries, veins. Lymphatic ducts, nodes, organs, tissues.
8. Respiratory - lungs, bronchial tree.
9. Digestive - mouth, esophagus, stomach, small intestine, colon, liver, pancreas.
10. Urinary - kidney, ureters, urinary bladder, urethra.
11. Reproductive:
 - 1) Ovaries, uterine tubes, uterus, vagina.
 - 2) Testes, epididymis, ductus deferens, glands, urethra, penis.

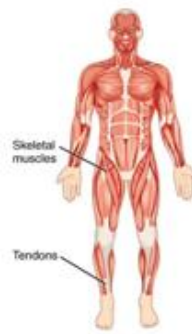Integumentary System



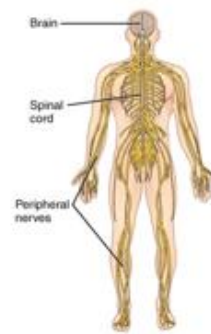
Skeletal System



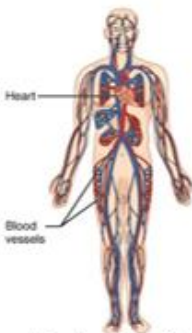
Muscular System



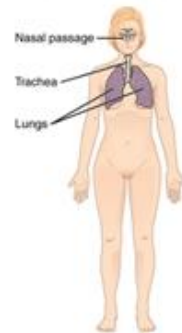
Nervous System



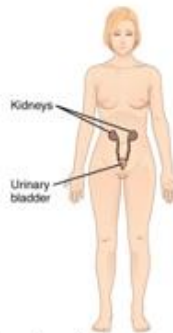
Circulatory System



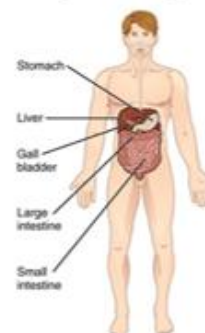
Respiratory System



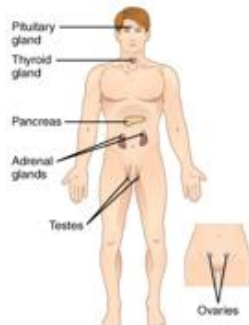
Excretory System



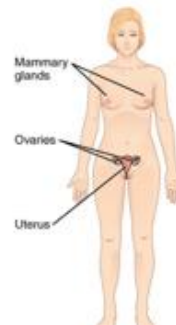
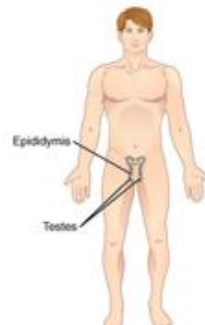
Digestive System



Endocrine System



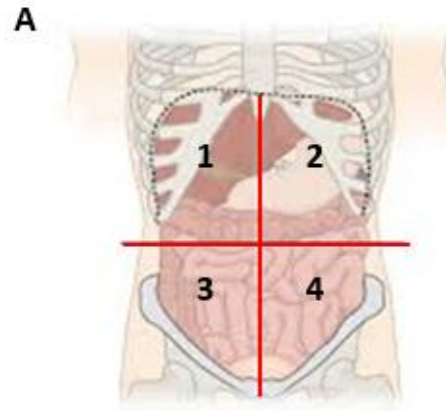
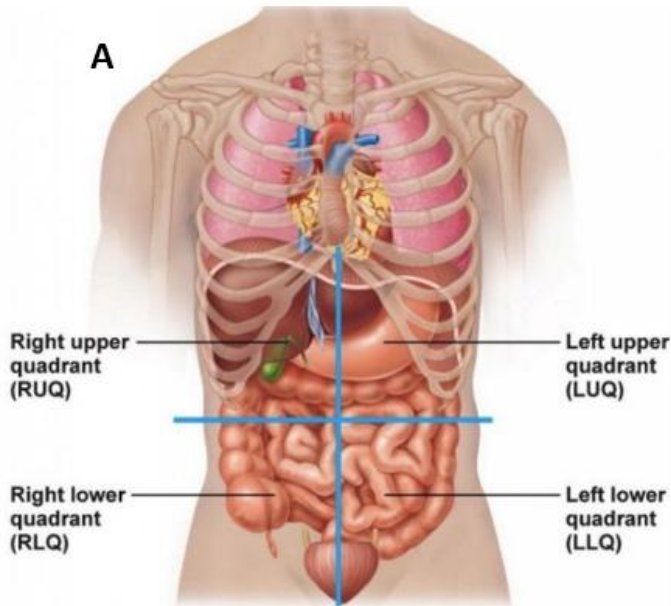
Reproductive Systems



IV. Regions of the Body – These can be represented by 4 or 9 quadrant divisions.

A. The 4 quadrants division:

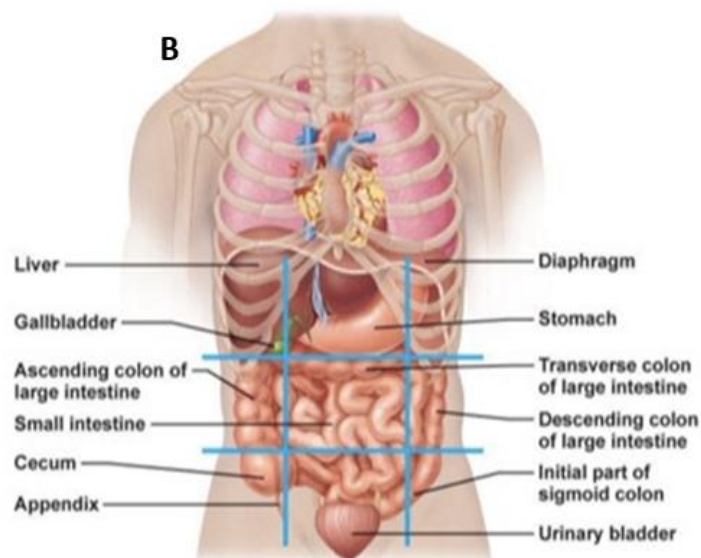
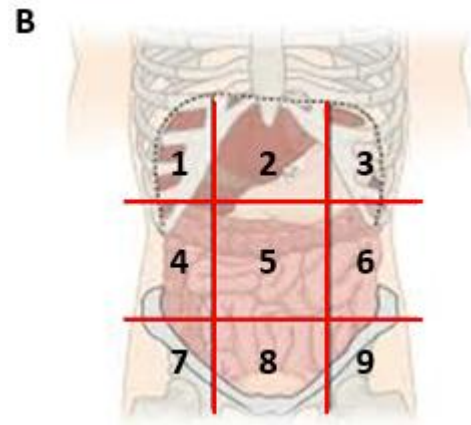
1. Right upper quadrant
2. Left upper quadrant
3. Right lower quadrant
4. Left lower quadrant



See your lab manual and/or any basic anatomy textbook for a diagram of these regions.

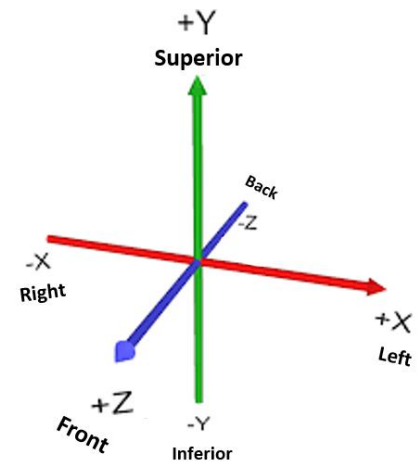
B. The 9 descriptive abdominopelvic regions:

1. Right hypochondriac
2. Epigastric
3. Left hypochondriac
4. Right lumbar
5. Umbilical
6. Left lumbar
7. Right iliac (inguinal)
8. Hypogastric
9. Left iliac (inguinal)



V. Planes of the Body

The planes of the body are geometric divisions used to partition the body into sections. The three-dimensional (3D) body can be viewed as having three axes, like the X, Y and Z of the graph at right. The human body is **bilaterally symmetrical**, meaning it can be divided into *two equal left and right halves*, around a central axis. The front (anterior) and the back (posterior) portions of the body are not symmetrical, and neither are the top (superior) and bottom (inferior) portions of the body. Combining the 3 axes with the 3 major planes of the body (seen in the illustration below), we see the **sagittal plane** is for left and right, the **coronal (or frontal) plane** is for front and back, and the **transverse plane** is for top and bottom.



The Three Planes of the Body

1. The Sagittal Plane

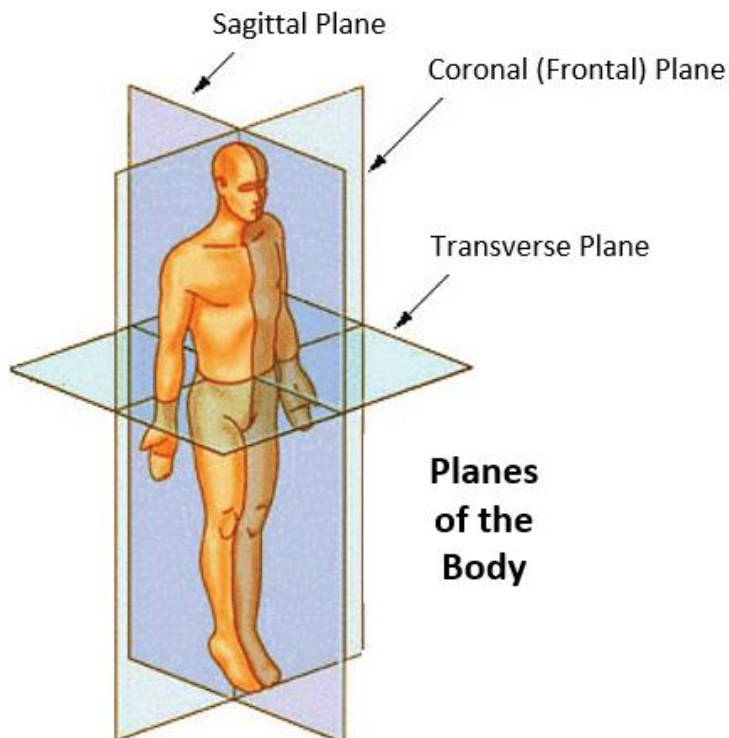
Divides body into left and right portions. This can be mid and parasagittal: Mid-sagittal means *equal* left and right portions, whereas para-sagittal means *unequal* left and right portions.

2. The Coronal (Frontal) Plane

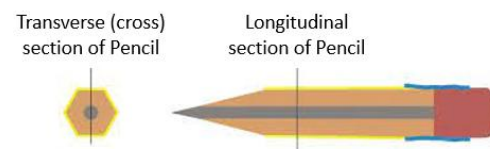
Divides body into anterior (front) and posterior (back) portions. Ventral is also a term for anterior, and dorsal is also a term for posterior.

3. The Transverse Plane

Divides body into superior and inferior portions. This is also called a cross sectional or horizontal plane, as it is the only plane that is perpendicular to the longitudinal axis of the body.



The 3D visualization of structures in books can be difficult. Try to think of common items first, like a pencil (see below) or an apple, and what it would be like to see them divided into different planes.



The figure to the left is very helpful in showing the 3 planes of the body in relation to each other. As we will see, it becomes essential to know these planes when examining histological sections (microscope slides) of various regions of the body, as well as the various anatomical models which are presented in different planes.

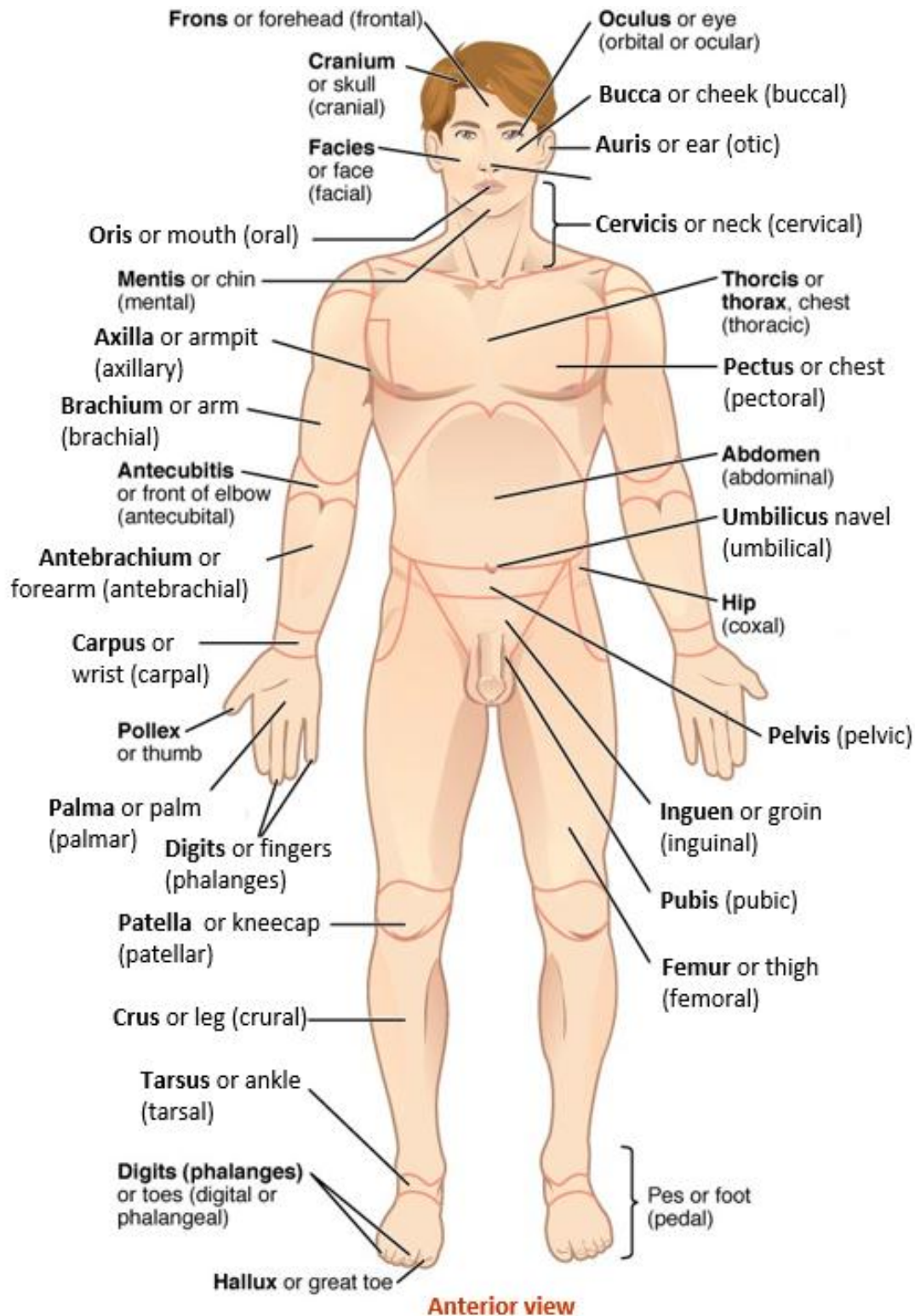
Table 1. Regions of the body described with anatomical landmarks and commonly terminology.

Anatomical Landmarks	Common Term
Cranium (Cranial)	Skull
Oris (Oral)	Mouth
Cervicis (Cervical)	Neck
Acromion (Acromial)	Shoulder
Thoracis (Thoracic)	Chest
Abdomen (Abdominal)	Belly
Gluteus (Gluteal)	Buttock
Inguen (Inguinal)	Groin
Pubis	Pubic
Axilla (Axillary)	Armpit
Brachium (Brachial)	Arm
Antecubitis (Antecubital)	Front of elbow
Olecranon	Elbow
Antebrachium	Forearm
Carpus (Carpal)	Wrist
Manus (Manual)	Hand
Pollex	Thumb
Digits (Phalanges)	Fingers
Femur (Femoral)	Thigh
Patella (Patellar)	Knee
Popliteus (Popliteal)	Back of knee
Crus (Crural)	Leg (front)
Sura (Sural)	Calf (back)
Tarsus (Tarsal)	Ankle
Calcaneus (Calcaneal)	Heel
Dorsum	Top of foot
Planta (Plantar)	Sole of foot

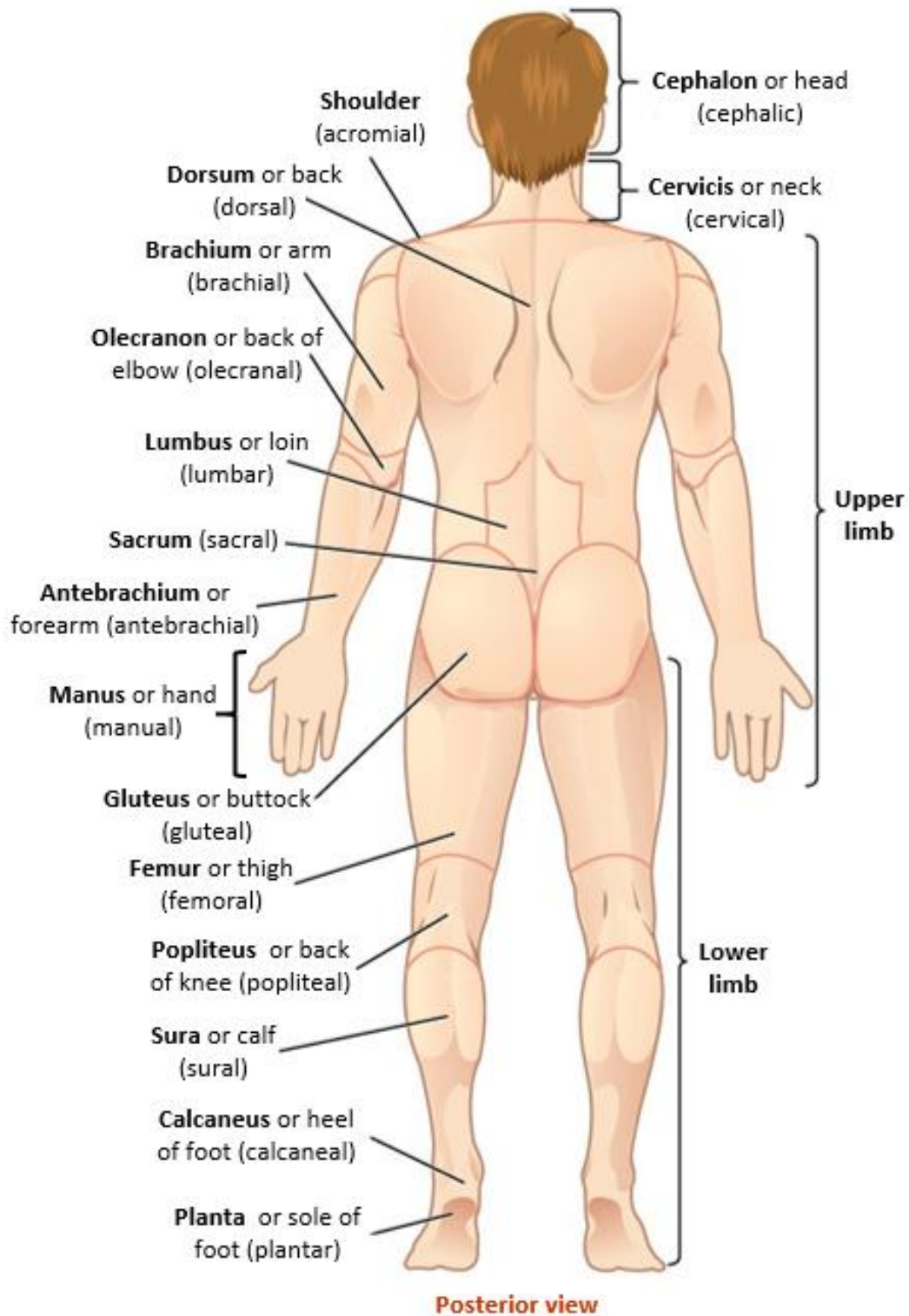
It is very useful to have knowledge of the anatomical landmarks for the “layperson’s” terminology.

Anatomical Regional Terms

The knowledge and use of **proper anatomical terms** is another way help to decrease ambiguity and increase precision, for which anatomy is renowned. Below are the essential body regional terms. Note that leg is not just any part of the lower limb, no. The term crus or crural is reserved for what we might call the shin region. Also, the thigh is not the leg. The term femoral is used to indicate the thigh.



Anatomical Regional Terms



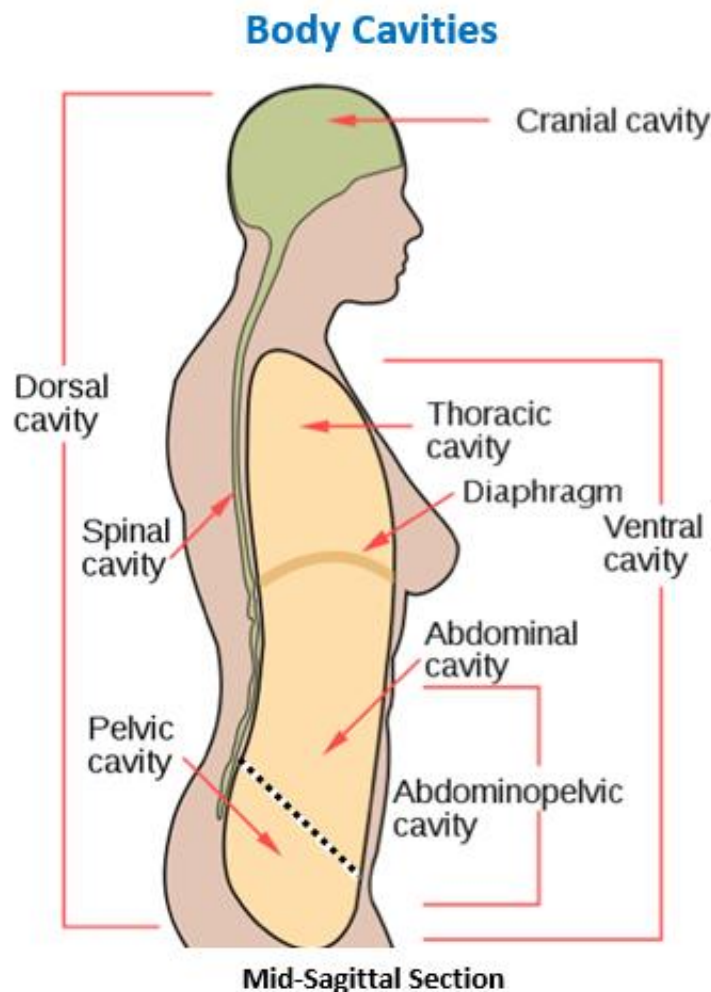
VI. The Body Cavities

Within the human body are cavities which help to contain, compartmentalize and protect the various organs and structures in the body, and also allow all structures to be interconnected. For these body cavities there is correct anatomical terminology. In the human, there are several body cavities, with additional, more discrete cavities within the larger cavities!

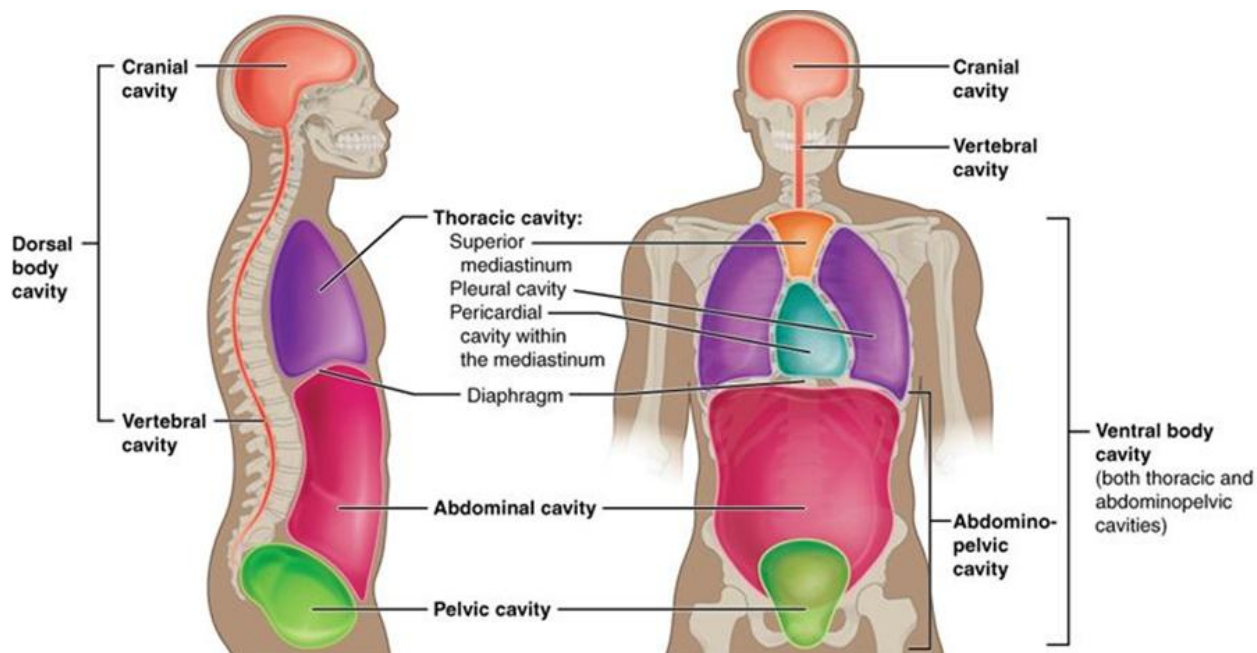
In general, there are 2 large separate body cavities in our bodies: **Dorsal** and **Ventral** body cavities.

1) The Dorsal body cavity (in the back), shown in green in the image below. Think of the dorsal fin of a whale, it is in the back. As you can see in the image below, the dorsal cavity has two cavities within it, the **cranial cavity** which is enclosed within the bones of the skull and houses the brain, and the **spinal cavity** enclosed by the bones of the vertebral column, which contains the spinal cord.

2) The Ventral body cavity (in the front), shown in yellow in the image below. The larger ventral cavity has two main divisions which are separated by the diaphragm (the primary muscle of respiration). It contains the **thoracic cavity** and the abdominopelvic cavity. The thoracic cavity is enclosed by the ribcage and contains the lungs (within the pleural cavities), mediastinum (the area in between the two lungs) and the heart (within the pericardial cavity). The **abdominopelvic cavity** contains many large internal organs, including the liver, stomach, intestines, with the bladder and reproductive structures situated within in the bony pelvic basin.



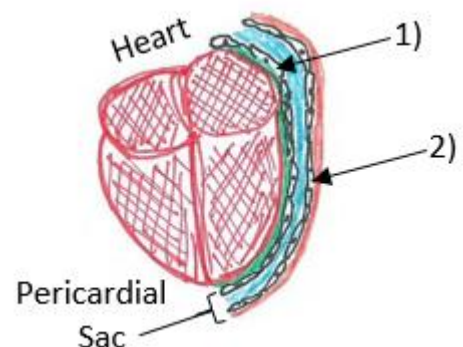
The image below (right) provides a more detailed visual of how the thoracic, abdominal, and pelvic cavities are arranged in the ventral cavity.



Summary of Body Cavities

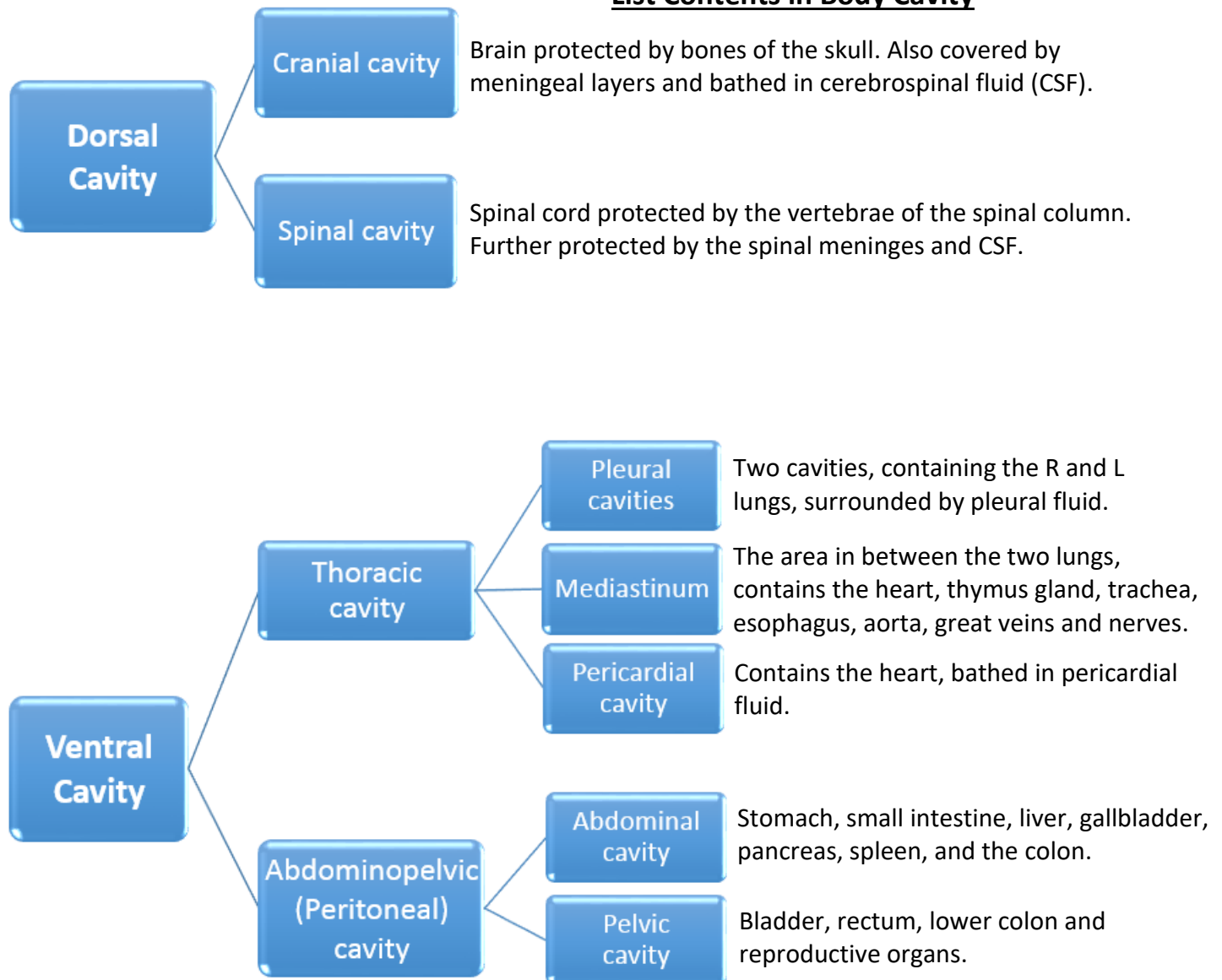
1. **Dorsal cavity** - contains brain and spinal cord (protected by cranial bones and vertebrae).
2. **Ventral cavity** is divided by the diaphragm (skeletal muscle for breathing) into:
 - a. **Thoracic cavity** which contains:
 - i. **Mediastinum**: Located between the lungs, it contains the esophagus, aorta, nerves, thymus and trachea, and the **pericardial cavity**, containing the heart.
 - ii. **Pleura cavity** containing the lungs (1 left and 1 right lung).
 - b. **Abdominopelvic cavity**. This cavity is separated by an imaginary plane into
 - i. **Abdominal cavity** containing most of the viscera.
 - ii. **Pelvic cavity** containing the urinary bladder, female reproductive and rectum.

All of the ventral internal body cavities mentioned above (pericardium, pleura and peritoneum) are lined by a **serous membrane** (see example in drawing at right). These body cavities are not directly exposed to the outside world (unlike the respiratory tract, for example) and need a moist and slippery surface in order to reduce the friction created by two surfaces moving across each other constantly. The example shows how the heart is in a 'cavity' which is created by the pericardial sac. We will go into much more detail about the various arrangements in the "Membranes" notes.



Flow Chart Showing the Body Cavities

List Contents in Body Cavity



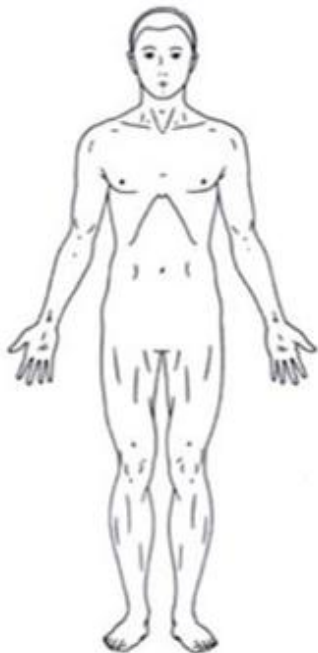VII. Anatomical Position

The anatomical position is a very useful way to create a **standard frame of reference for the body**. This position is used as a set orientation when describing a person's anatomy so that everyone will be using the same frame of reference for the body, again to reduce any ambiguity.

The anatomical position, or standard anatomical position, is standing upright, feet together, facing forward, arms at your sides with palms facing forward (anterior), as seen in the illustration below. This is called the **supine** position. When the palms are facing posteriorly, it is called the **prone** position.

Note: The “prone position” is a medical term for *lying flat on your stomach*, while the “supine position” means lying flat on your back. This is different to the standing anatomical position.

Here is an example of where the standard anatomical position is very useful. If a person were to ask: Is the stomach inferior to the diaphragm? The answer will not depend on whether someone is standing on their head or bent over, etc. We can safely assume the description and the answer is with reference to the anatomical position seen below. Most often, if the term anatomical position is used, it is referring to a person standing, unless otherwise indicated. Again, when a subject is laying down, then supine refers to laying on their back and prone is laying on their stomach.



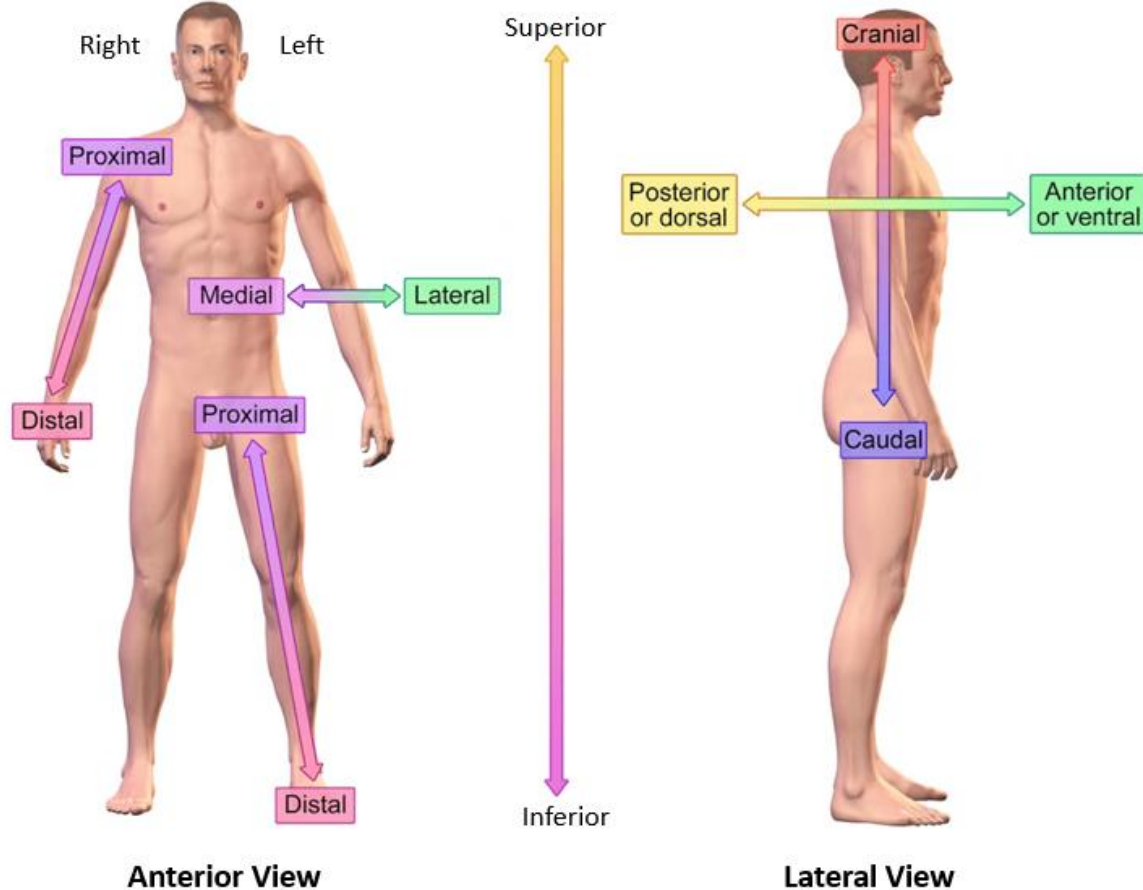
Anatomical Position

- **Standing upright**
- **Head and eyes directed straight ahead**
- **Upper limbs at the sides**
- **Upper limbs slightly away from trunk**
- **Palms facing forward**
- **Thumbs pointing away from body**
- **Lower limbs parallel**
- **Feet flat on the ground and facing forward**

VII. Anatomical Directions – these are terms used to describe specific directions in the body.

- A. Superior / Inferior
- B. Posterior / Anterior
- C. Dorsal / Ventral
- D. Deep / Superficial
- E. Distal / Proximal
- F. Lateral / Medial

Anatomical Directional References



Review of the Cell

Can you guess, approximately, how many cells are in the human body?

The human body is made up of ... the number is said to be from 50 to 60 trillion, but how anyone counted or even calculated that is another story. Human cells can vary dramatically in size, shape and function. If we stop to think about how amazing this is, we will be very impressed with ourselves. These cells act as a well-coordinated community that functions as a whole organism. When we are balanced and in good health these cells do not compete with or destroy each other – on the contrary, they cooperate and focus on specific tasks that the body calls for. If cells are competing and destroying each other, using resources but providing no function or even obstructing the function of other cells, this is indicative of a stressor or an imbalance. We do not focus on pathologies (disease states) in this course, we are concerned with the amazing anatomy of a healthy, balanced body.

Of these cells, there are *only about 200 different types of cells* in the human body. For example, hepatocytes are found in the liver, neurons help make up nervous tissue, osteocytes are found in bone tissue, adipocytes are found in fat (adipose) tissue, and so on. Note how important the names are! What type of cells is a erythrocyte? The prefix erythro means red and cyte means cell. What about leukocytes? The prefix leuko is a Greek term meaning white.

Within the human body, most cells have some basic properties in common and we will very quickly review them on the next page.

I. Cell Structure

A. Cell Membrane Functions as almost everything!

1. It creates the cell boundary, separating the inside of the cell from the outside.
2. Allows for adhesion and attachments to other membranes.
3. Has receptors for hormones, neurotransmitters and other signals for communication.
4. Has identifying markers to indicate function to other cells.

B. Special Features on cells may include:

1. Cilia - these are hair-like structures that arise from the exposed (apical) end of some cells. Their role is for the movement of substances across surface of the cell, e.g., mucous.
2. Microvilli - extensions of cell membrane, to increase the surface area of cell for exchange, e.g. to increase the rate of absorption.
3. Flagellum - a whip-like structure for the movement of the entire cell, e.g., spermatozoa.

II. Cell Membrane Permeability – what substances can move across the plasma membrane of a cell?

The Degree of Permeability Varies:

1. Impermeable - this type of membrane restricts the passage of all molecules.
2. Selectively permeable - this cell membrane lets certain molecules through but not others.
3. Highly permeable - lets almost anything through the cell membrane.

III. Cell Attachments and Junctions

- A. Tight junction - near free surface (apical end) of epithelium, watertight seal.
- B. Desmosome - lightly tacks cells together, usually deep to the surface (basal end).
- C. Hemidesmosomes - tethers cells to basement membrane where cells are anchored.
- D. Gap junction - physical opening between two cells, permits direct communication of ions, etc.

IV. Cell Names

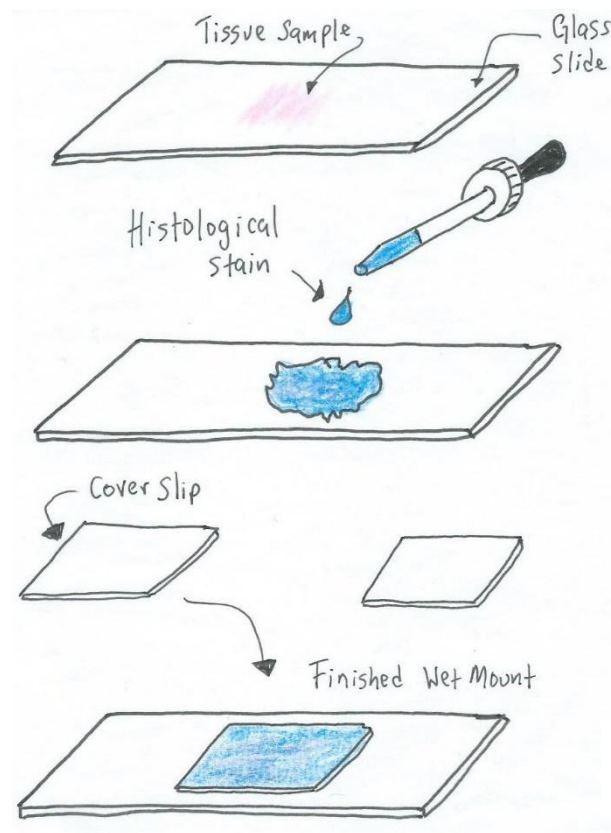
The names of cells often indicate their location and function. In general, the term -cyte means a mature cell that resides in and maintains that tissue (e.g., a chondrocyte, in cartilage). Hepatocytes are found in the liver, neurons are for nervous system communication and adipocytes are found in adipose tissue, where they store triglycerides (fat). Various cell types can also have special endings, for example the suffix (ending) blast indicates a cell that makes or builds something (e.g., a fibroblast makes fibers). The suffix -clast means those which breakdown structures (e.g., an osteoclast breaks down bone matrix).

Cells are considered the unit of life and it is assumed you are already familiar with the basic concepts of cell structure. The first lab session is designed to reacquaint you with major cell structures and introduce you to microscopy. Knowing how to use the microscope to examine cells, tissues and organs is a powerful skill and that is another important goal of the first lab sessions of anatomy that are called **Microscopy**.

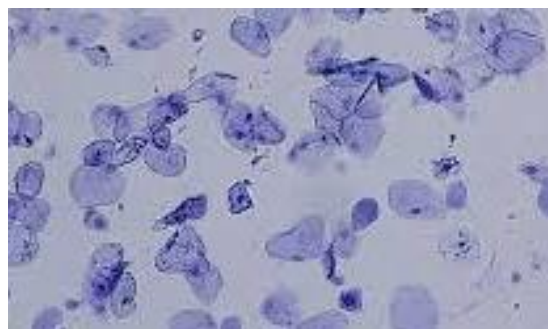
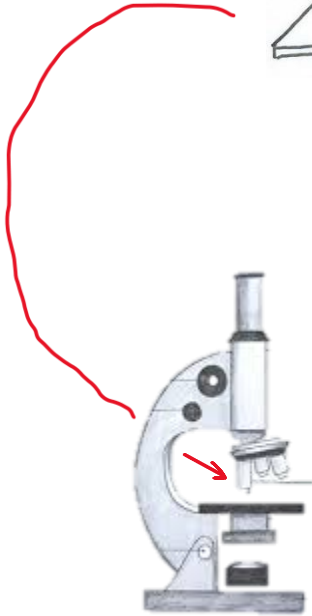
Summary of Objectives for Introduction to Anatomy

1. To understand the language of anatomy and its specialized terminology.
2. To introduce levels of organization, body regions, the anatomical and directional terminology that will be used during the course.
3. To introduce the body cavities and lining membranes that will be seen during the course.
4. To define cytology and introduce the basic concepts involved in cellular organization.
5. To become familiar with the names of some cells and the tissues they form.

Below is a diagrammatic overview of a very basic histological technique practiced in our anatomy lab, called a **wet mount** preparation. This is very easily created from epithelial cheek cells of the mouth.



Ready for viewing under the microscope!



As we will see in the next section and in the anatomy lab, the image above (at right) is what the cheek cells look like down the microscope after they are stained with methylene blue. Making a wet mount will serve as our introduction into the world of **Histology**.