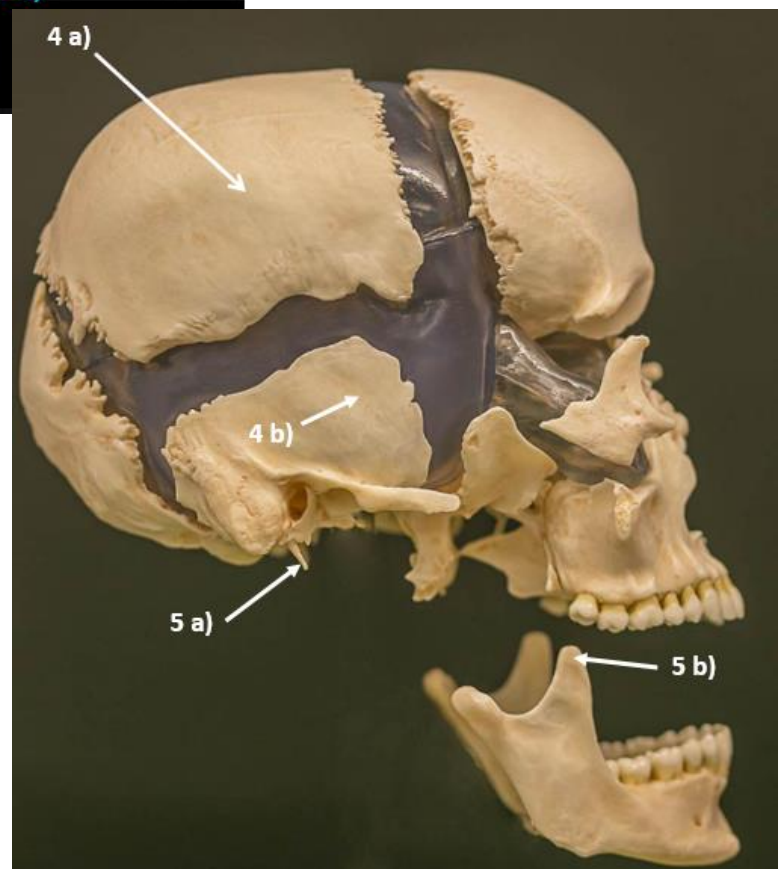
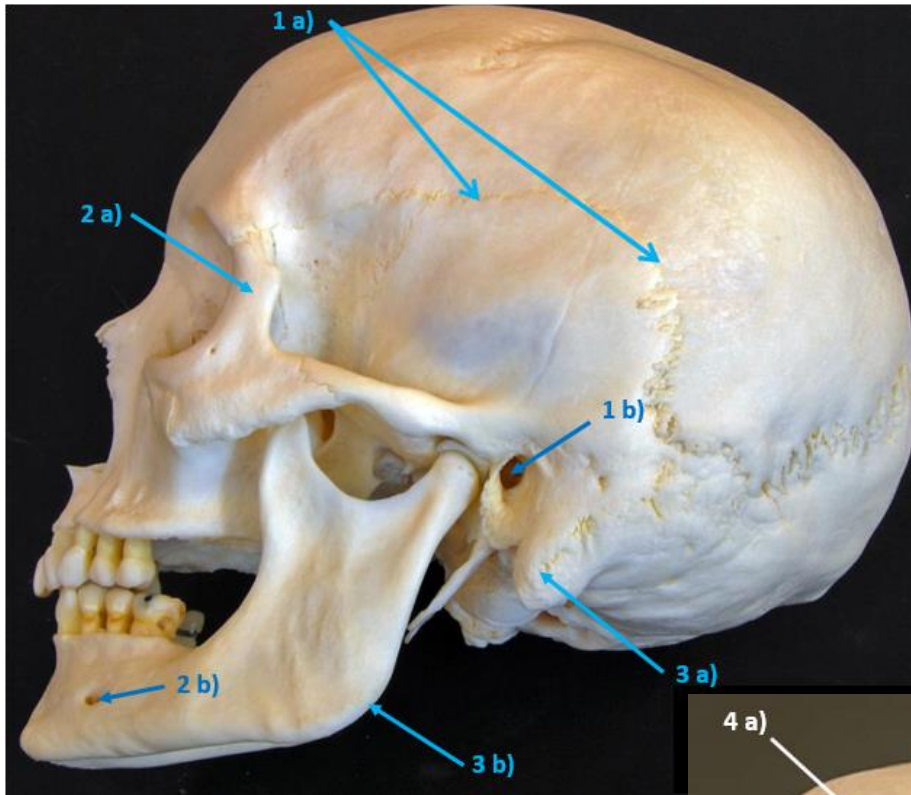
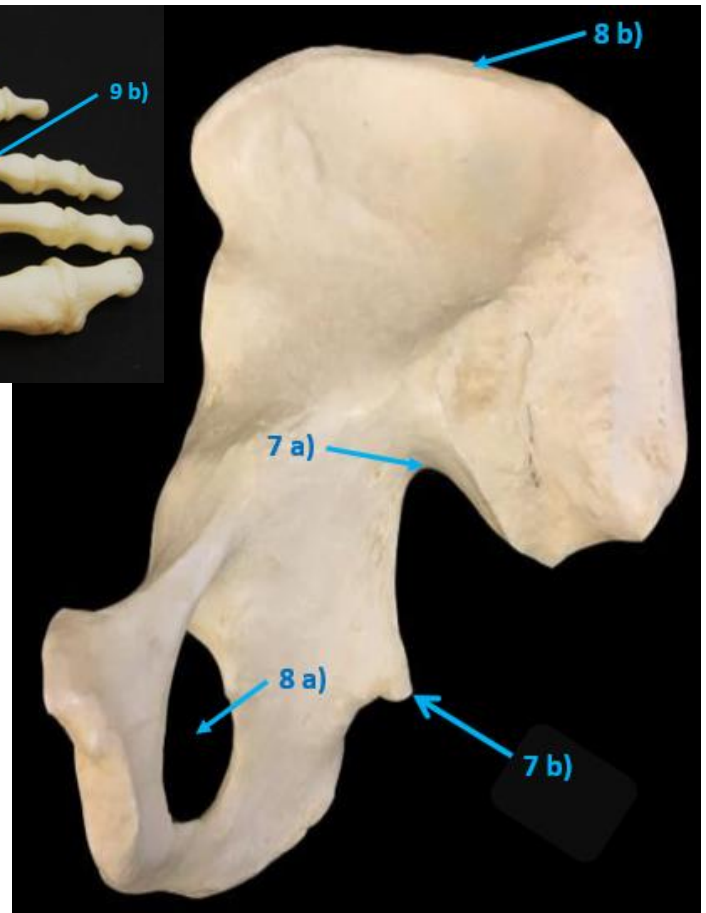
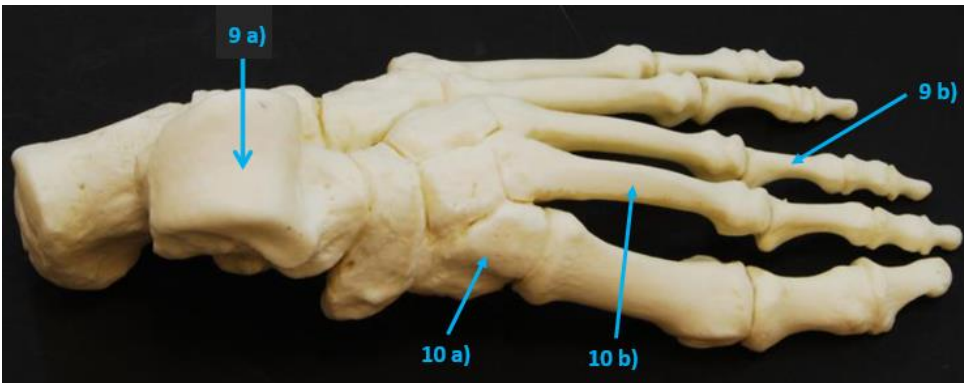


## Anatomy (BIOL 230) Bone Practice Exam (Lab and Lecture)

**Part 1:** Name the following structures indicated by the numbered arrows on the photographs.

*\*The structure indicated will be exactly where the arrow is pointing, or it will be the bone, region or specific process indicated. Let the structure list in our lab manual serve as our guide to the structures shown here.*





**Please write the answers next to appropriate #'s below:**

- |             |             |
|-------------|-------------|
| 1 a) _____  | 1 b) _____  |
| 2 a) _____  | 2 b) _____  |
| 3 a) _____  | 3 b) _____  |
| 4 a) _____  | 4 b) _____  |
| 5 a) _____  | 5 b) _____  |
| 6 a) _____  | 6 b) _____  |
| 7 a) _____  | 7 b) _____  |
| 8 a) _____  | 8 b) _____  |
| 9 a) _____  | 9 b) _____  |
| 10 a) _____ | 10 b) _____ |

**Part 2:** Complete these multiple choice questions, please provide the **answers on a scantron!**

*\*Use the Anatomy Lecture Notes online and any other resource to find the answers.*

1. Which of the following are considered **short bones** in terms of classification of bones by shape?

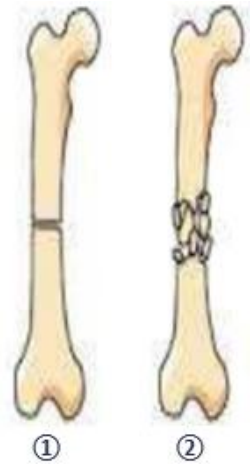
- a) bones of the ribcage    b) bones of the leg    c) bones of the forearms  
d) bones of the tarsals    e) bones of the skull

2. Name the types of fractures **shown to the right**: ① = \_\_\_\_\_; ② = \_\_\_\_\_.

- a) ① = green stick; ② = spiral.    b) ① = transverse; ② = comminuted.  
c) ① = transverse; ② = impacted.    d) ① = comminuted; ② = displaced.

3. What specific structure articulates with the os coxae at the acetabulum?

- a) greater trochanter of femur    b) head of humerus    c) base of sacrum  
d) auricular surface of sacrum    e) head of femur



4. The two main constituents of bone are: 1) \_\_\_\_\_ that gives flexibility; and 2) \_\_\_\_\_ that gives rigidity.

- a) organic; calcium    b) inorganic: collagen    c) organic; inorganic    d) organic collagen; inorganic

5. Red bone marrow

- a) is found only in the femur of adults    b) is found in the adult os coxae    c) consists of adipose tissue  
d) produces all blood cells    e) b and d

7. Which of the following cells are considered the **stem cell** for bone tissue?

- a) mesenchymal cells    b) osteoprogenitor cells    c) osteoclasts    d) osteocytes    e) osteoblasts

8. Which statements about **paranasal sinuses** are true?

- a) they are located in all of the cranial bones    b) they are not present in the ethmoid bone  
c) they make the skull lighter    d) their mucus secretions are not connected to the nasal cavity

9. Osteoblasts

1. have the ability to divide    2. dissolve bone matrix    3. make fibers in bone matrix  
4. maintain bone matrix    5. are located inside a lacuna  
a) 3 and 5    b) 2 and 5    c) 4, 3 and 1    d) 3 and 4    e) 3 only

10. Which of these is not a normal function of the skeletal system?

- a) mineral storage in the body    b) protection of underlying tissues    c) a and b  
d) synthesis of vitamins    e) a, b and c